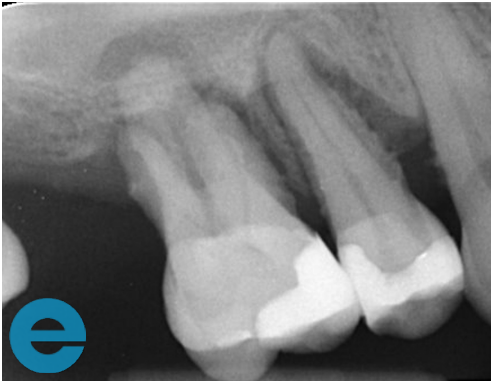
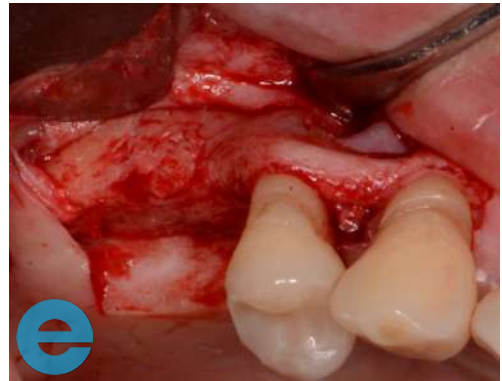
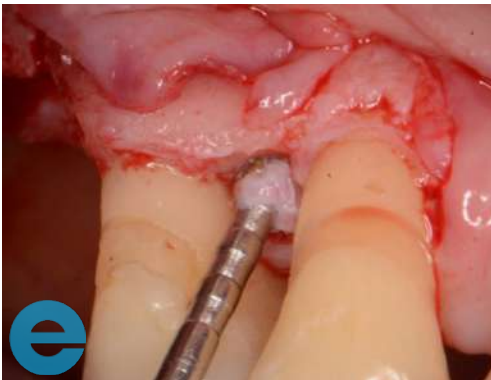SINUS LIFT AND PERIODONTAL GRAFTING



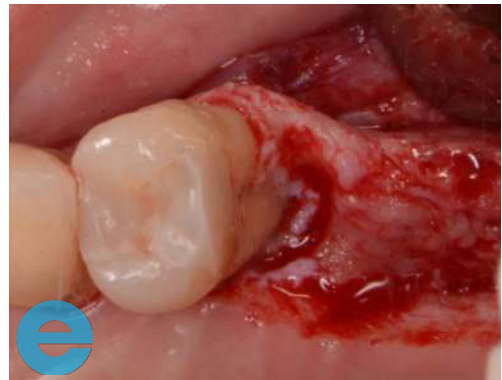1. Both the 15 and 16 were Grade 3 mobile. The patient wanted to save the teeth



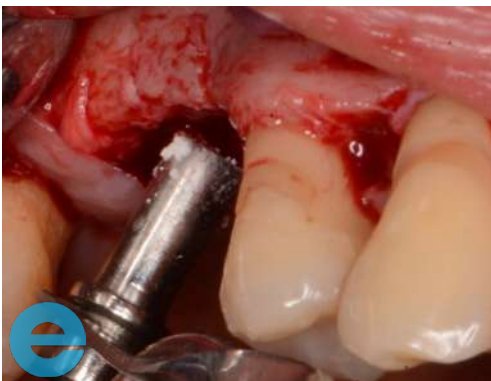2. The 16 had to be removed and the 15 was deep scaled - two months later a flap was raised



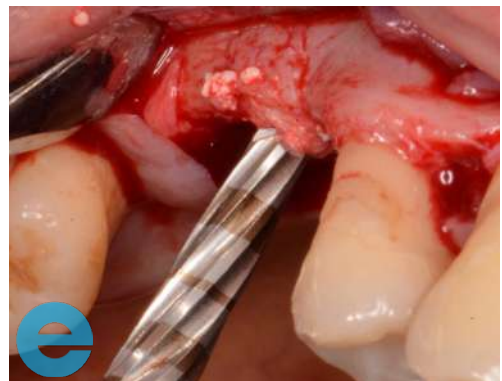3. Site was cleaned using EthOss® Degranulation Burs, especially palatally



4. Site was cleaned using EthOss Degranulation Burs, especially palatally



5. Sinus augmentation performed on site of 16 using EthOss bone grafting material and graft gun

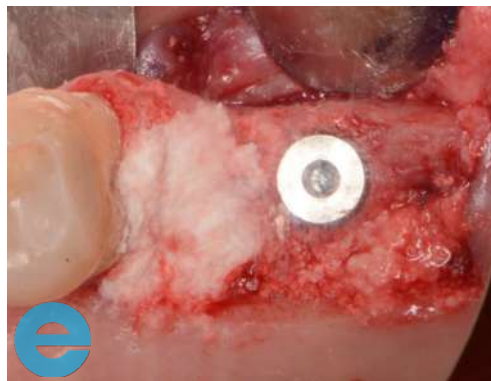


6. Versah drills for further sinus augmentation

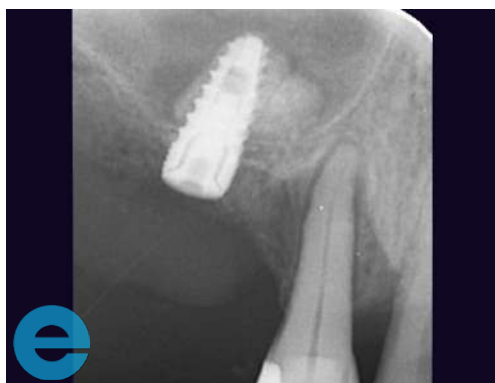SINUS LIFT AND PERIODONTAL GRAFTING



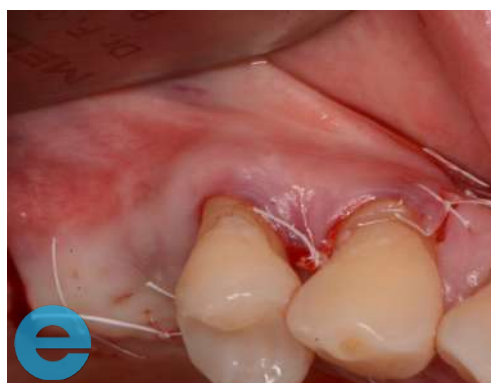7. EthOss bone grafting material placed on container



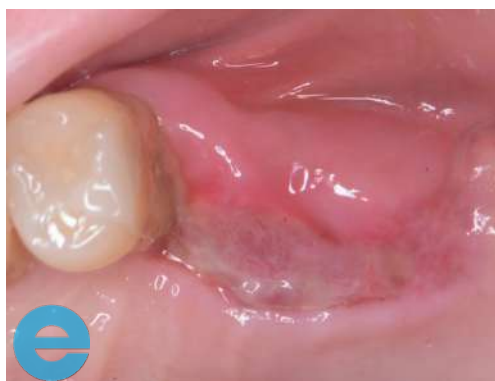8. Grafted around the 15 with EthOss bone grafting material



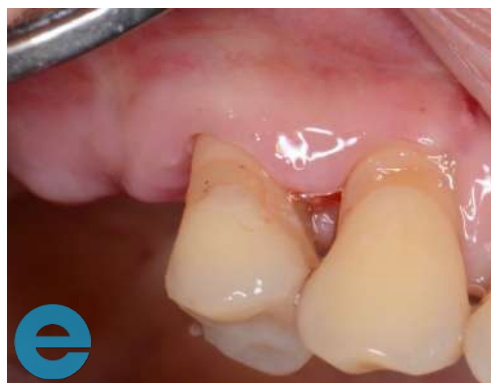9. Radiograph of 15 with implant and EthOss bone grafting material



10. Sutured closed with PTFE (Coreflon)

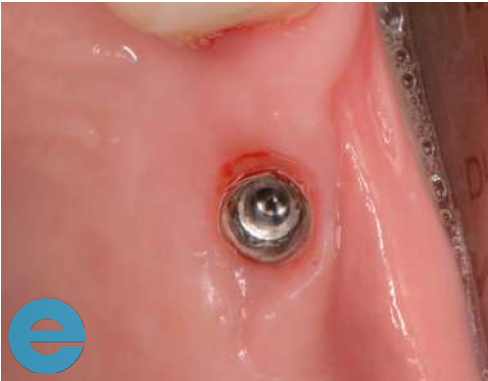

11. Sutures removed at 5 days, shows healing by secondary intention

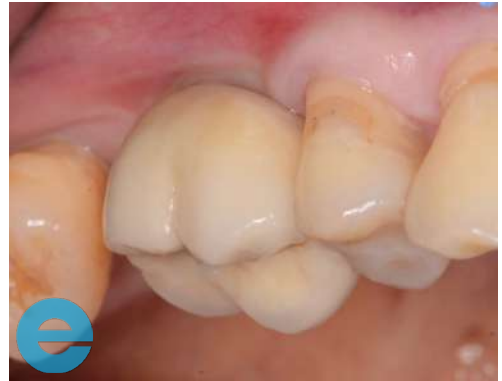

12. Healing by secondary intention

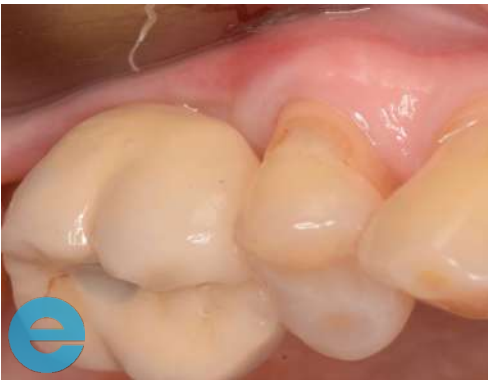SINUS LIFT AND PERIODONTAL GRAFTING



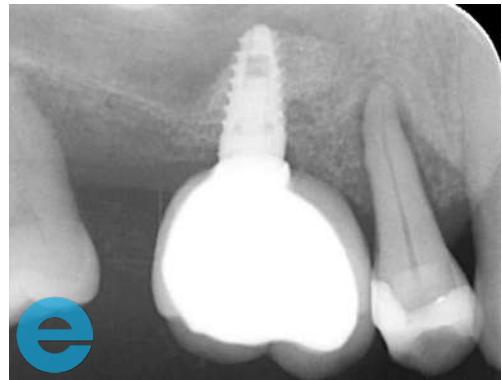
13. Loading at 3 months, bone around 15 now very solid and patient



14. Loading at 3 months, bone around 15 now very solid and patient happy



15. Loaded 4 months - everything very stable



16. Loaded 4 months - radiograph



GROW STRONGER®

USEFUL RESOURCES

RECOMMENDED CLINICAL PROTOCOL

Clinical study showcasing recommended clinical protocol for EthOss bone grafting material

[Download](#)

SURGICAL GUIDELINES

The official recommended guide on how to use EthOss bone grafting material

[Download](#)

HOW TO MIX ETHOSS BONE GRAFTING MATERIAL

Explainer video

[Watch](#)