ethOss®

Grow Stronger®_

Volume 5

CASE STUDY

CONTENTS

If you would like to be involved in the next International EthOss® Case Study Book please send your cases to

info@ethoss.dental

For further information on the case studies from this book or to enquire about EthOss® Bone Graft, please contact our team:

Email: info@ethoss.dental

Tel: +44 (0)1535 843106

Ethoss Regeneration Ltd ("Us", "Our") will not be liable, or accept responsibility for, any use or application of the products, or the techniques, mentioned in any case studies, articles, newsletters, blogs, brochures or any other media prepared by us or contained in our literature, website, social media channels or any other communications. It is the clinician's responsibility to follow the official guidance related to each of the products as produced by the relevant manufacturer and ensure they are adhering to recommended methods and uses and are complying with the correct techniques for use of the products. All case studies and clinical examples are for illustrative purposes only. Please always refer to the product manufacturer's guidance as to how to use any products and techniques mentioned in these case studies.

Long Term Outcomes
04 - 25

Peri-implantitis
26 - 47

Periodontal Regeneration
48 - 69

Cysts
70 - 97

Advanced Surgical Techniques
98 - 122

Long Term Outcomes - 5 Year Review

Reviewing long-term cases, such as those featured in this chapter, is both fascinating and rewarding. They showcase the real long-term benefits of using modern resorbable synthetic graft materials, with bone allowed to remodel and respond to stress over time without the interference of any long-term remnant graft particles. I see the benefits of this every day in my clinical practice, with cases appearing to get better and better as years go by.

What makes this case series particularly powerful is the variety of different techniques on display. It demonstrates that, even with different techniques and individual preferences, when we respect biology the results are consistent, stable, and lasting.

As healthcare professionals, it is in our nature to wish to improve our patient's health and minimise downsides associated with surgery. As surgeons, our role is to create the right environment for healing to happen. With the right regenerative protocols, we can direct this healing potential and allow the bodies healing process to work with regenerative protocols, improving outcomes.

I'm grateful to the contributors for taking the time to review their patients and share their outcomes.

Dr. Stuart Kilner

Head of Education



With special thanks to all our contributors

Dr Nicholas Busuttil-Dougall

Dr Dominic O'Hooley

Dr Vanessa Suárez Córdoba

Dr Jakub Batycki

Dr Ludwig Hansson

Cyst removal, buccal defect and immediate implant placement

PATIENT BACKGROUND

39 year old male
Non-smoker

This patient presented with a missing 14 and a failing 13 due to a failed endodontic treatment with a large periapical radiolucency (cyst). The cyst left a large apical defect alongside a huge buccal fenestration defect.

The upper right 3 was removed along with the cyst. The area was carefully cleaned and osteotomies were carried out using osseo-densification protocol. A wet mix was applied to allow the material to run into the defect completely, and the implants were placed. Following this, a drier mix of EthOss® Bone Graft was added buccally and crestally, stabilising the graft.

This case demonstrates the use of EthOss Bone Graft alongside immediate cyst management and implant placement.



Dr Nicholas Busuttil-Dougall



1. Initial CBCT



2. Cyst fragments



3. Defect after cyst removal

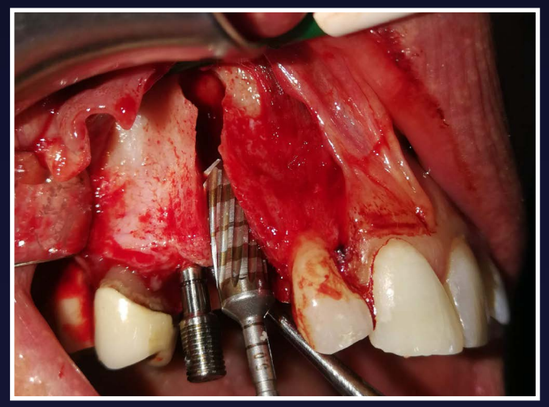

4. Osteotomies were carried out using osseo-densification protocols

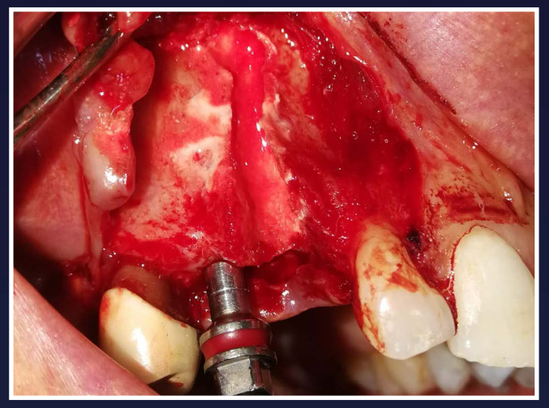

5. Wet layer palatally

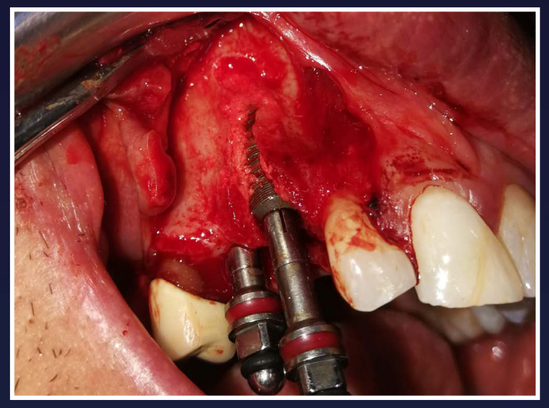

6. Implant intersection in wet mix

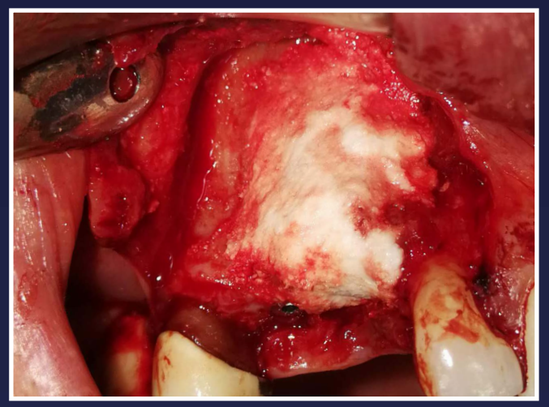

7. Dry layer bucally



8. Dry layer crestally

01

Cyst removal, buccal defect and immediate implant placement

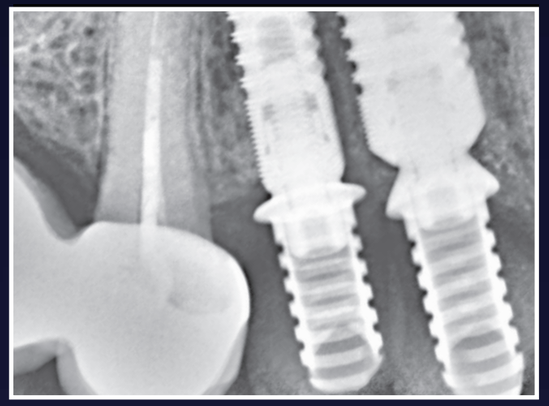

9. Post-op radiograph

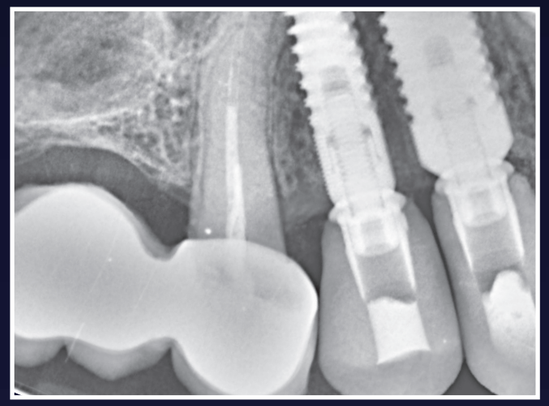

10. Radiograph 4 months post-op - fit final crown

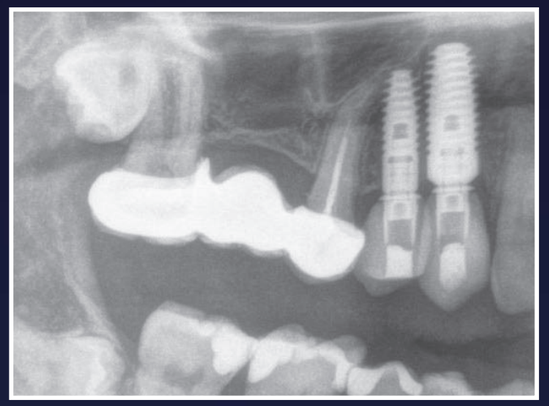

11. Radiograph - 5 years post-op

ethOss Grow Stronger

Immediate implant placement and graft in extraction socket

PATIENT BACKGROUND

55 year old male
Non-smoker

This patient presents with failing LR5 (45) & LR6 (46) due to secondary decay. The teeth were extracted, and the infected tissue was removed.

EthOss® Bone Graft was used to circumferentially build up the jump gap around the socket and the healing abutment.

This case demonstrates the option to leave EthOss Bone Graft uncovered in the clinical situation, as shown with excellent long-term hard and soft tissue outcomes.



Dr Dominic O'Hooley



1. Pre-op radiograph



2. Pre-op CT scan

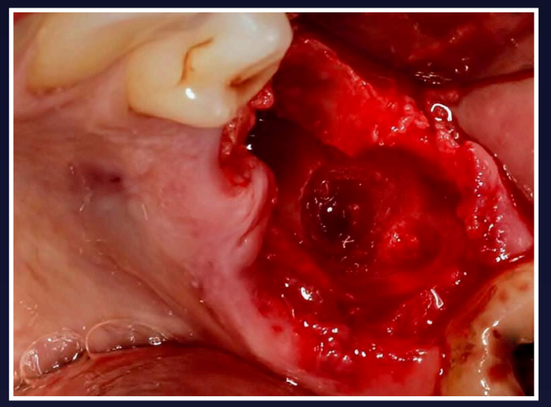

3. Extractions, removal of infective tissue, flap design. Large defect

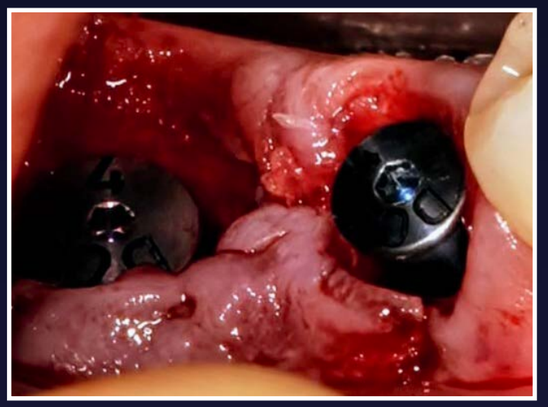

4. Implant placement - 2 Southern implants with deep conical connections



5. EthOss® Bone Graft placement, 1cc into jumping gaps and defect

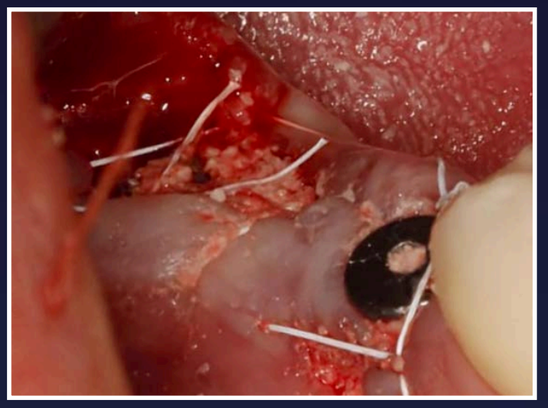

6. Transmucosal closure with PTFE sutures



7. Healing at 12 weeks

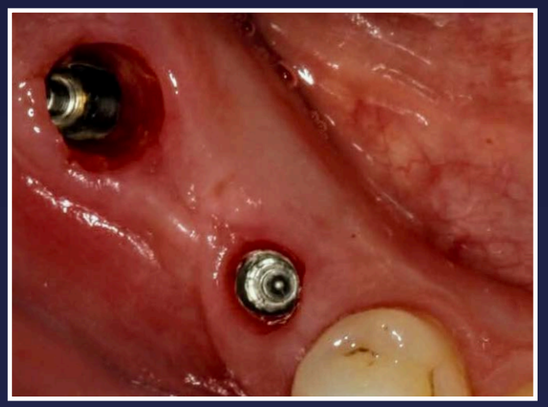

8. Implants and gingival collars



9. Fitted crowns

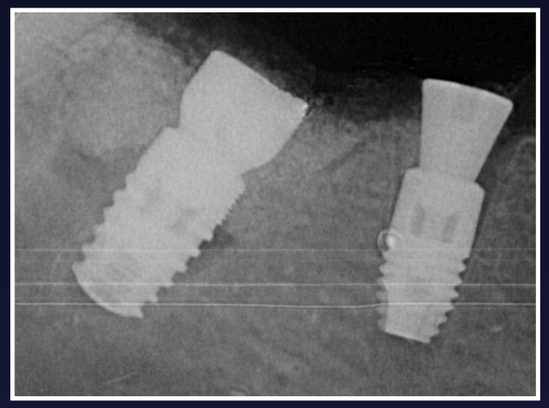

10. Radiograph at placement showing EthOss Bone Graft

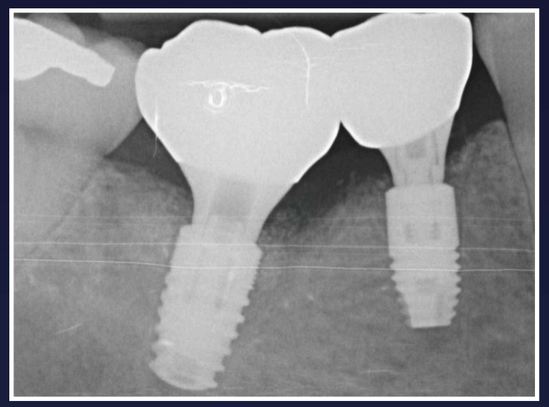

11. Radiograph at placement showing fit of crowns

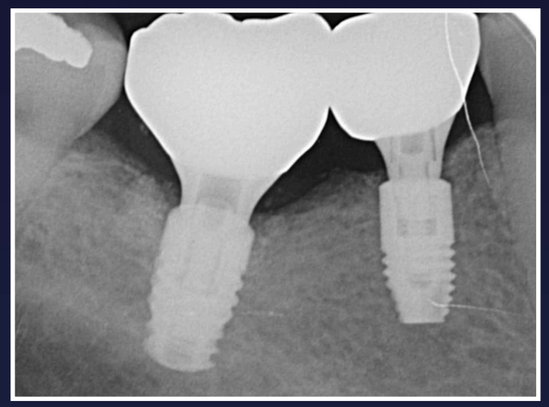

12. Radiograph - 1 year post-op

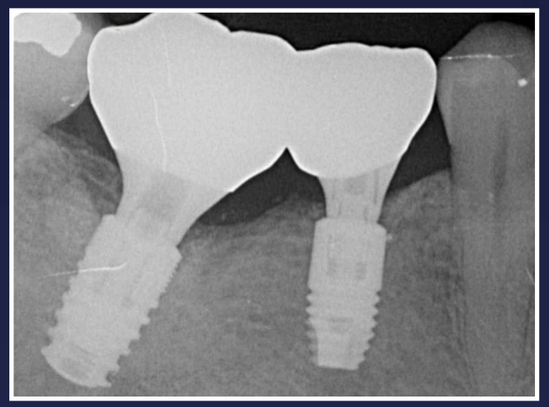

13. Radiograph - 3 years post-op



14. Review - 5 years post-op



15. Review - 5 years post-op

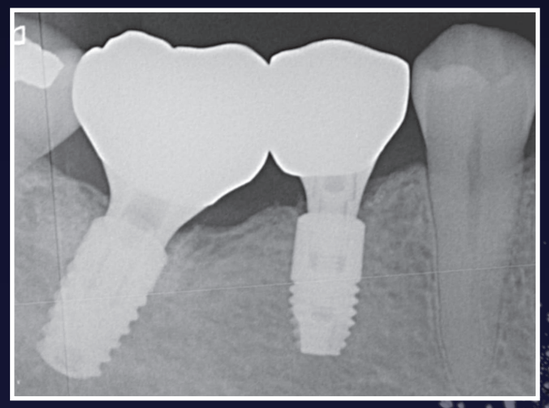

16. Radiograph - 5 years post-op

ethOss® Grow Stronger

Socket grafting and delayed placement

PATIENT BACKGROUND

42 year old female
Non-smoker

A healthy patient with no allergies or medication.

This patient presented with a complaint of pain whilst chewing and occasional unpleasant taste associated with the UR2 (12). Further investigation showed a vertical root fracture.

This patient was managed with a socket preservation/ regeneration technique; the implant was placed at 12 weeks along with a trephine biopsy for histological study.

This case demonstrates excellent clinical outcome alongside further histological investigation demonstrating successful bone regeneration.



Dr Vanessa Suárez Córdoba



1. Vertical root fracture

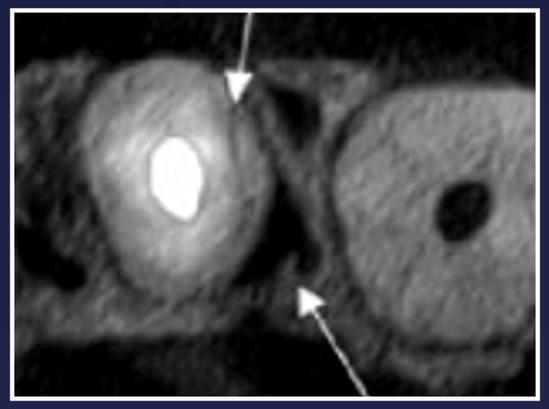

2. Hypodense line denoting fracture

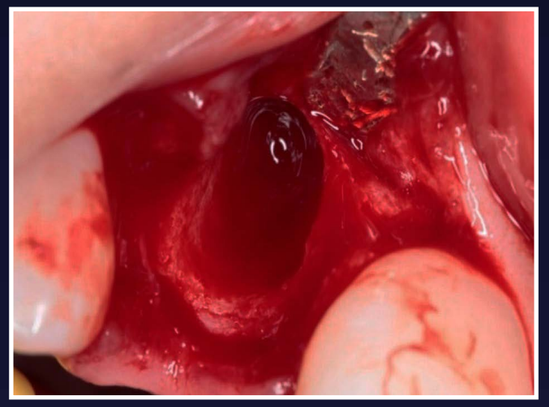

3. Dental extraction

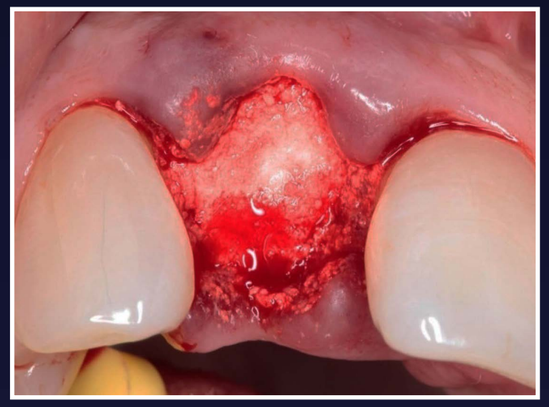

4. Socket graft with EthOss® Bone Graft

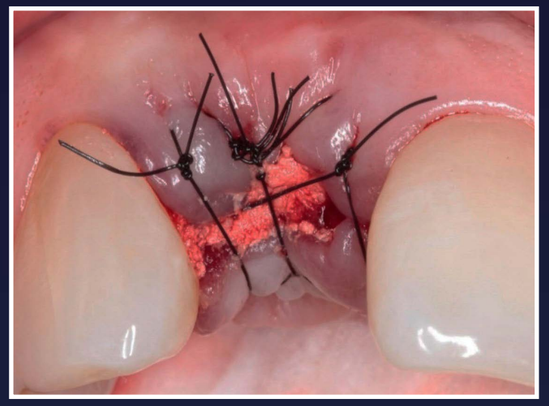

5. Site sutured close, small exposure will heal over by secondary intention



6. Provisionlisation using a clinical crown splinted to next teeth

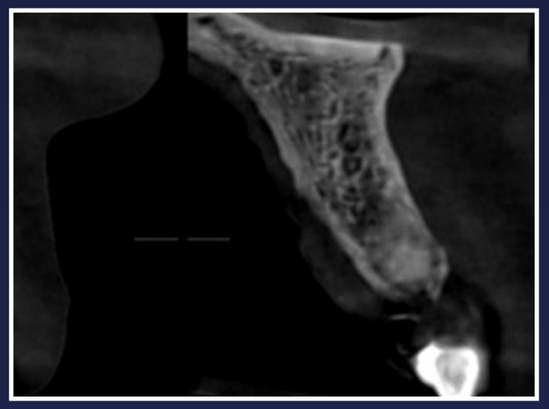

7. CT scan - 12 week post-op



8. Surgical re-entry. Before implant placement and during the surgery, a trephine biopsy is taken

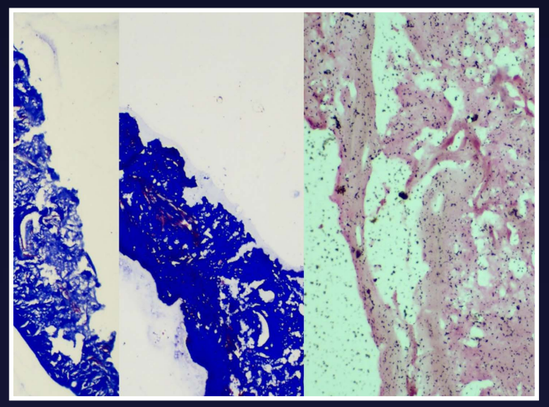

9. Histological results demonstrating the outcome of successful bone regeneration

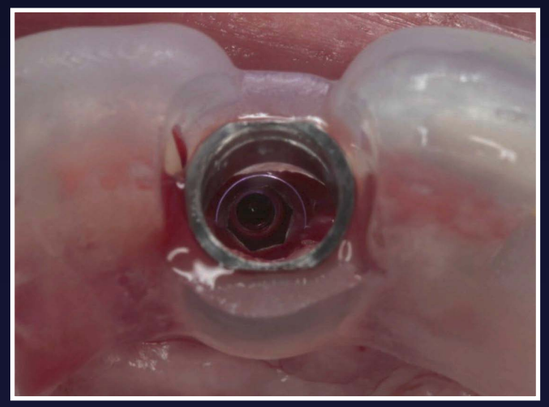

10. Dental implant placement using guided surgery



11. Preparation of provisional temporary crown



12. Provisionalization



13. Profiling of peri-implant tissues



14. Final crown installation



15. Palatal view

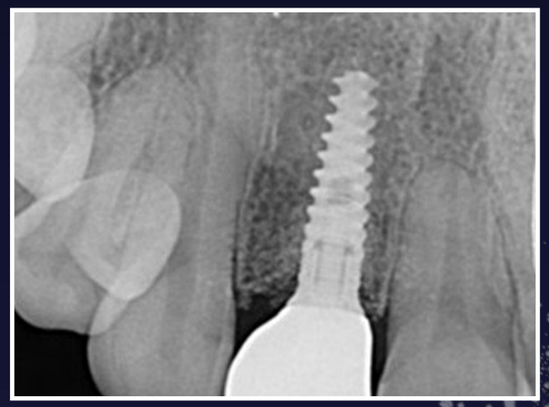

16. Final radiograph and follow-up of the adaptation of the definitive crown. Bone is still healing coronal to the dental impant



17. Photographic control of the clinical case - 4.5 years later

ethOss Grow Stronger_

Simultaneous apicectomy and implant placement

PATIENT BACKGROUND

74 year old male
Non-smoker

A simultaneous apicectomy and implant placement was performed in the maxillary aesthetic zone (canine and premolar region). Following root-end resection, the apex was sealed with a small amount of mineral trioxide aggregate (MTA). The apical defect was grafted with 0.7cc of EthOss® Bone Graft (B-TCP composite). Concurrently, implant placement was carried out, and a tissue-level implant was inserted. Buccal bone was augmented using the remaining EthOss Bone Graft material. Primary closure was achieved using PTFE sutures.

The patient was reviewed over a 5-year follow-up period. The surgical site demonstrated excellent healing with stable hard and soft tissue contours. No complications or failures were observed.



Dr Jakub Batycki

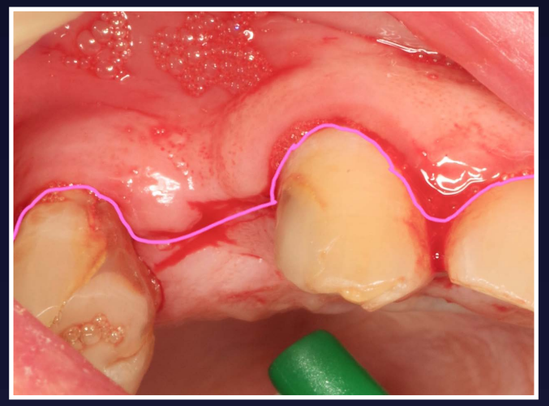

3. Long crestal incision



4. Apicetomy - small amount for MTA and EthOss® Bone Graft to restore defect

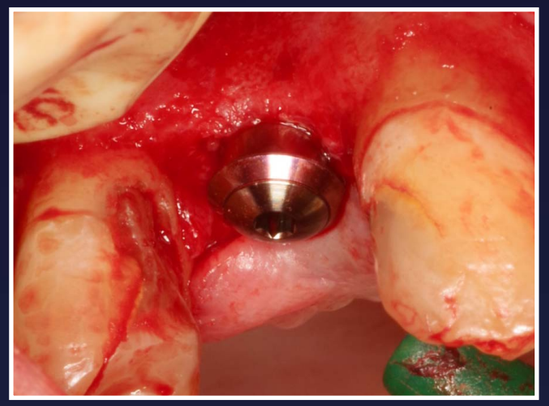

5. Position of tissue level implant



6. Buccal surface regeneration with EthOss Bone Graft



1. Pre-op site assessment CBCT



2. Pre-op clinical photography



7. Sutures



8. Review - 12 weeks post-op

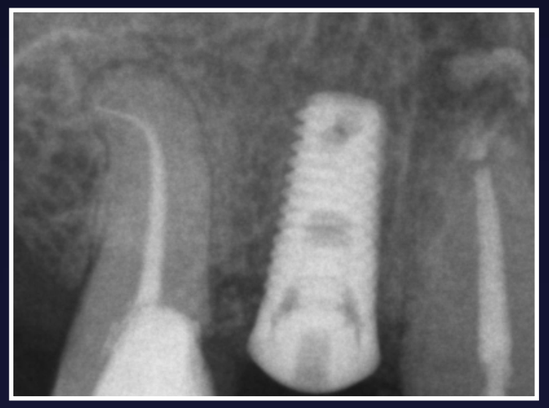

9. Radiograph - 12 weeks after placement

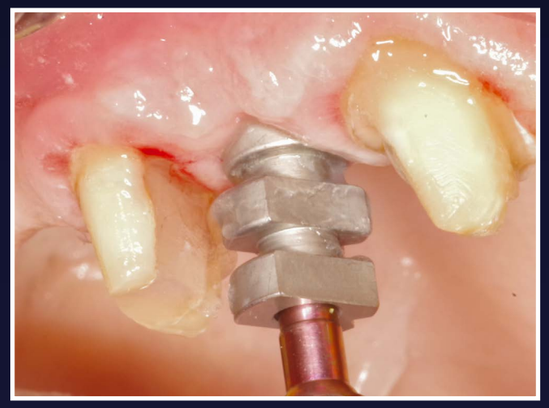

10. Impressions



11. Post-op radiograph



12. Crowns fit and restoration of implant



13. 14 weeks post-op - soft tissue healing



14. Review - 6 months post-op



15. Review - 3 years post-op



16. Radiograph - 3 years post-op



17. Review of soft tissues - 5.5 years post-op



18. Radiograph - 5.5 years post-op

ethOss Grow Stronger

Ridge regeneration with simultaneous implant placement

PATIENT BACKGROUND

65 year old female
Non-smoker

The referring dentist experienced difficulty extracting tooth 46, and the patient is seeking an implant in that area. Previously, the patient underwent orthodontic treatment, during which eight premolars were extracted. As a result, a first molar is currently positioned in the space formerly occupied by the premolars.

This case demonstrates single surgery management of a large buccal defect, regaining lost hard and soft tissue volume to give this case an excellent long-term outcome. The implant was restored using an early-loading protocol, with placement of the permanent crown 4 weeks after implant installation.



Dr Ludwig Hansson



1. Pre-op situation, lack of bone and soft tissue



2. CBCT shows a lot of bone loss due to referral dentist damaging the site



3. Pre-op radiograph

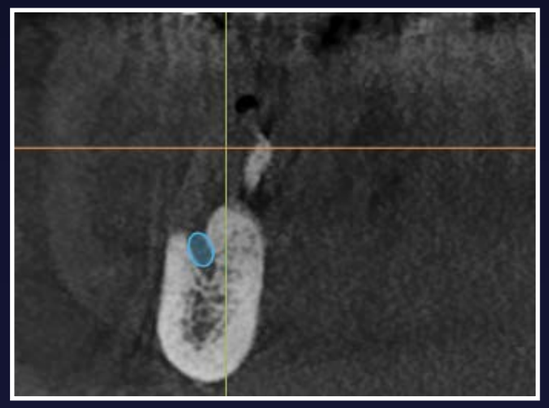

4. Very close to the mental foramen



5. Initial flap for inspection

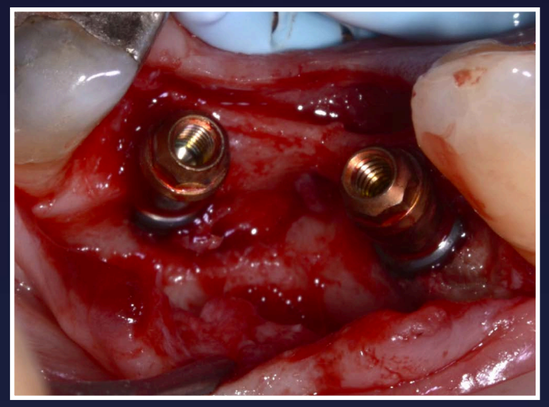

6. AnyRidge implants placed with high torque and ISQ; 3.8mm permanent Octa abutments torqued to 35 Ncm

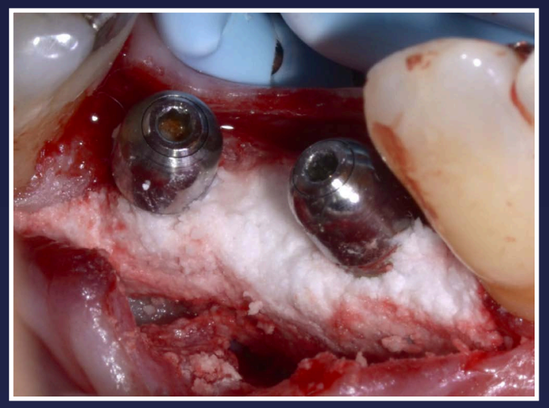

7. Healing caps and EthOss® Bone Graft in place

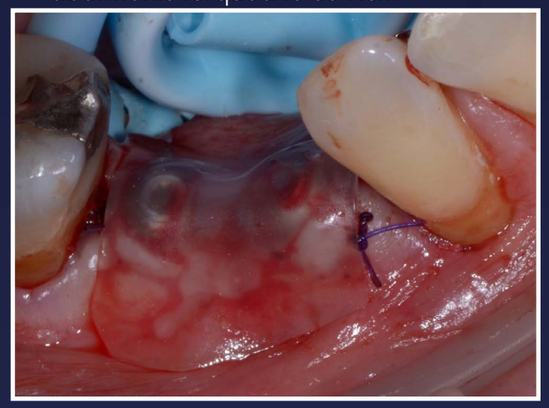

8. Ora-aid in place after surgery

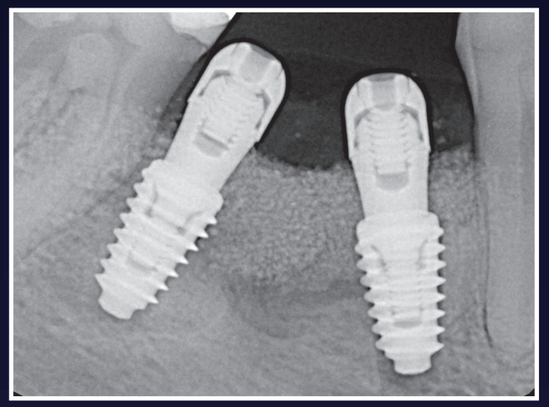

9. Radiograph - 2 weeks post-op. Suture removal

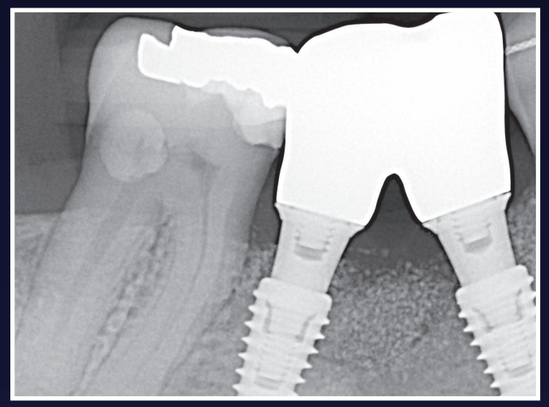

10. Radiograph - 4 weeks post-op

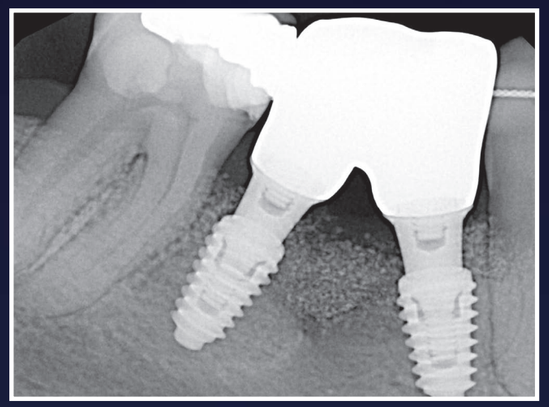

11. Radiograph - 4 weeks post-op

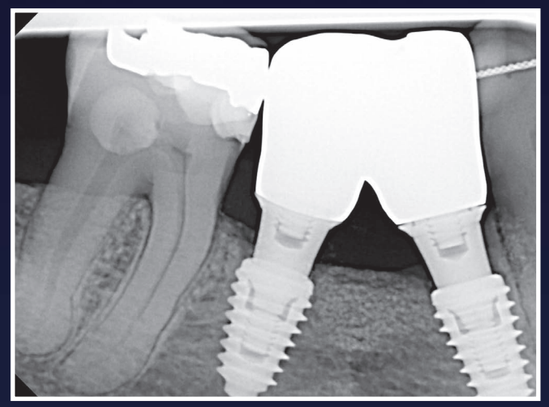

12. Radiograph - 2 years post-op



13. Radiograph - 3 years post-op

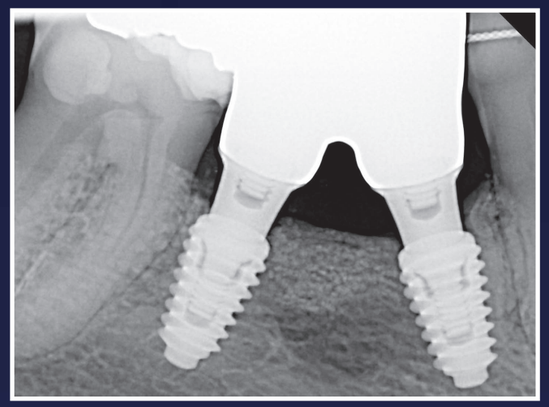

14. Radiograph - 4.5 years post op



14. Clinical situation - 4 years post-op



15. Clinical situation - 4 years post-op

Peri-implantitis

Peri-implantitis is a challenging complication in implant dentistry. Characterised by inflammation and progressive loss of bone around the neck of the implant, its successful management requires more than surface decontamination alone.

As clinicians, our role is to create the conditions that allow the body's natural healing processes to function effectively. This requires careful surgical execution and the use of materials that respect biology, particularly in compromised and inflamed sites.

Resorbable synthetic grafts offer advantages in these situations by providing temporary structural support while allowing regeneration to progress towards vital host bone. EthOss® is used throughout this case series as part of a biologically driven regenerative approach.

The cases presented in this chapter reflect a range of peri-implantitis scenarios managed using different techniques and clinical preferences. Despite this variation, the outcomes demonstrate that when biological principles are respected, stable and predictable regeneration is achievable. We thank the contributing clinicians for sharing their work and follow-up.

Dr. Stuart Kilner

Head of Education



With special thanks to all our contributors

Dr Stefan Anca

Dr Alberto Fernández De Valderrama Martinez

Dr Renukanth Raman

Dr Hussein Asaria

Dr Karol Badeja

Long-term xenograft failure with peri-implantitis

PATIENT BACKGROUND

45 year old female
Non-smoker

Implant placed in 2014 with a buccal xenograft and provisional crown. Eight years later, the patient returned for definitive restoration. Clinical and radiographic assessment revealed buccal bone resorption, exposed implant threads, and retained xenograft particles.

Loose xenograft particles were removed, the implant surface was decontaminated using titanium curettes, and the defect was grafted with EthOss® Bone Graft. The provisional crown was re-seated during healing.

Three-year follow-up demonstrated stable peri-implant tissues, healthy gingiva, and regenerated buccal bone over the implant abutment.



Dr Stefan Anca



1. Implant in good prosthetic position and the buccal estethic flap (Prof. M. Steigmann) for the bone graft - bovine xenograft in 2014



2. Healing after 2 weeks from implant placement

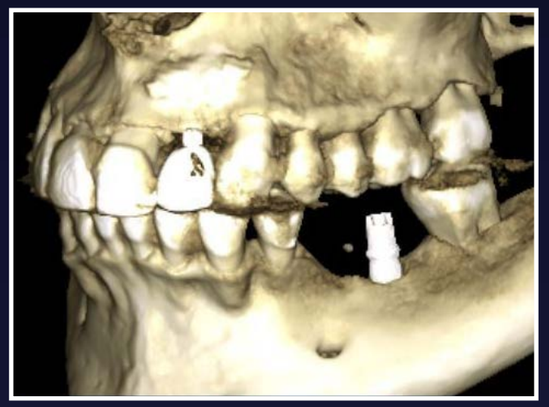

3. The situation after 7 years: you can see clearly the xenograft on the buccal plate



4. 8 year recall - provisional crown was fractured and required remaking



5. Crown removed. You can see a grey shade through the gum



6. Flap raised - implant has thread exposed. Bone and loose xenograft particles cleaned with steel curretes. Implant cleaned with titanium curretes. Xenograft particles visible in site

Long-term xenograft failure with implantitis



7. The EthOss® Bone Graft graft in place



8. The provisional crown back on implant and the sutures



9. Sutures removal at ten days



10. Healing after ten months, before the final crown



11. Three years recall: situation is stable, the gum is pink and healthy



12. CT scan 3 years after EthOss® Bone Graft for peri-implantitis: the buccal bone is healed over the titanium abutment

Long-term xenograft failure with peri-implantitis



13. CT scan 3 years after EthOss Bone Graft for peri-implantitis: the buccal bone is healed over the titanium abutment

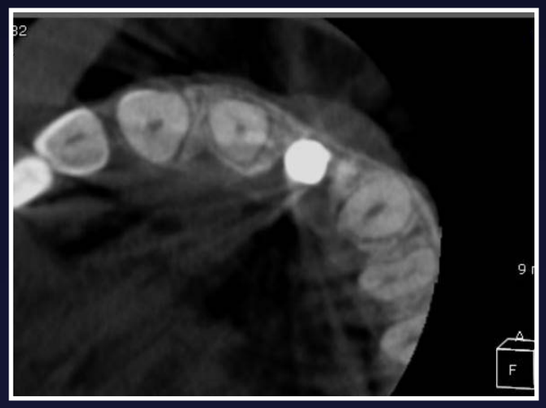

14. CT scan 3 years after EthOss Bone Graft for peri-implantitis: the buccal bone is healed over the titanium abutment



15. CT scan 3 years after EthOss Bone Graft for peri-implantitis: the buccal bone is healed over the titanium abutment

ethOss Grow Stronger_

Advanced peri-implant bone loss

PATIENT BACKGROUND

60 year old male
Non-smoker

Medical history includes obesity and obstructive sleep apnoea. The implant was placed approximately 20 years previously and featured an external hex connection.

Advanced peri-implant bone loss with deep vestibular and palatal probing depths.

Following flap elevation, peri-implant defects were identified on both vestibular and palatal aspects. The implant surface and defect were thoroughly debrided and grafted with EthOss® Bone Graft. Primary closure was achieved with sutures.

Radiographic review at 2 months demonstrated early bone regeneration and stabilisation of peri-implant tissues.



Dr Alberto Fernández De Valderrama Martinez



1. Pre-op radiograph

2. Pre-op situation



3. Palatal probing depth



4. Vestibular probing depth

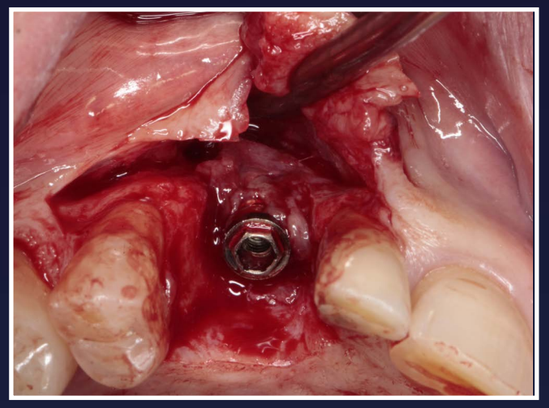

5. Intra-operative peri-implant pocket

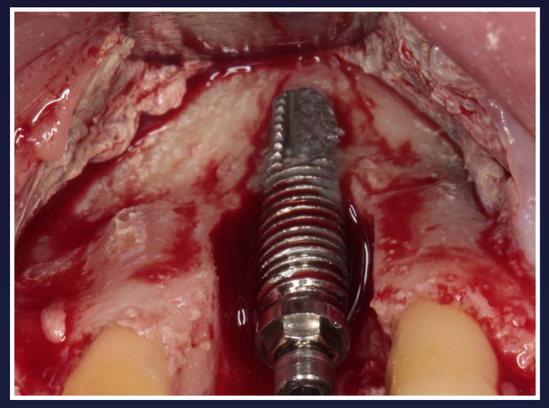

6. Intra-operative vestibular defect

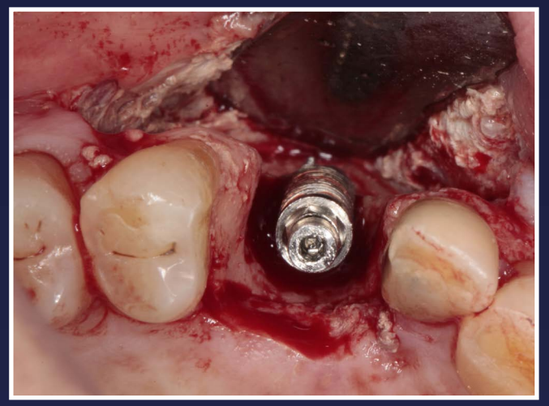

7. Intra-operative palatal defect

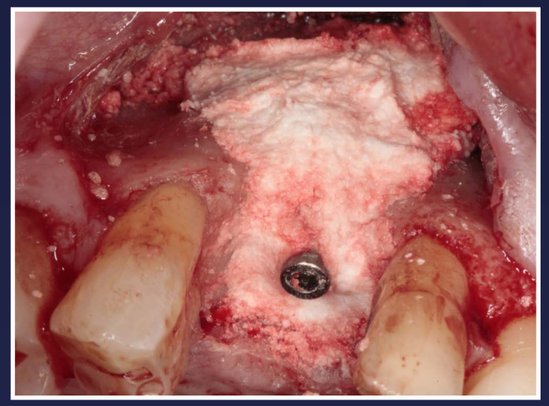

8. EthOss® Bone Graft vestibular

Advanced peri-implant bone loss

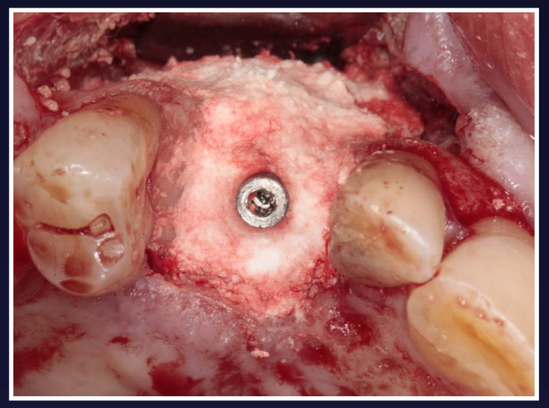

9. EthOss Bone Graft palatal



10. Sutures

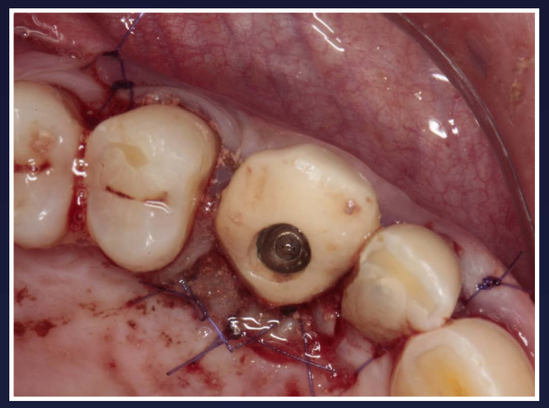

11. Sutures

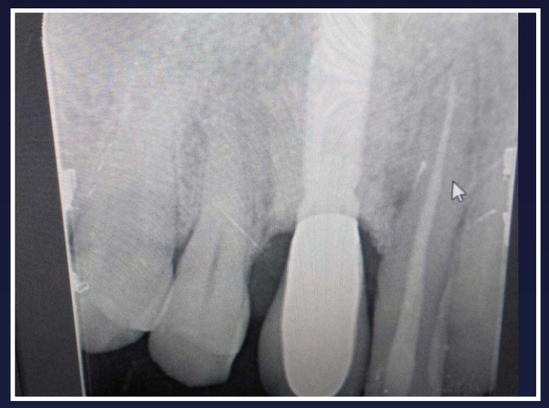

12. Radiograph on surgery day

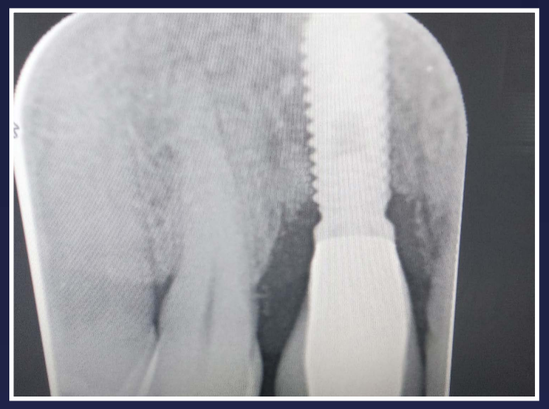

13. Radiograph - 4 months post-op

Retrograde peri-implantitis

PATIENT BACKGROUND

56 year old male
Non-smoker

History of chronic periapical infection secondary to failed endodontic treatment prior to implant placement.

Six months post-loading, the patient presented with a persistent draining sinus. Radiographic examination revealed a radiolucent lesion involving the apical portion of the implant fixture, consistent with retrograde peri-implantitis.

A semilunar incision was made at the mucogingival junction, and a mucoperiosteal flap was raised. Granulation tissue was removed using titanium curettes. Mechanical implant surface debridement was performed using an air-abrasive device, followed by chemical disinfection with 0.2% chlorhexidine. EthOss® Bone Graft biphasic synthetic graft was placed, allowed to stabilise, and the flap was secured with 5/0 PTFE sutures.



Dr Renukanth Raman



1. Implant fixture was placed and restored 6 months post-loading, the patient presented with a persistent draining abscess apical to the mucogingical junction on the buccal aspect of the peri-implant mucosa

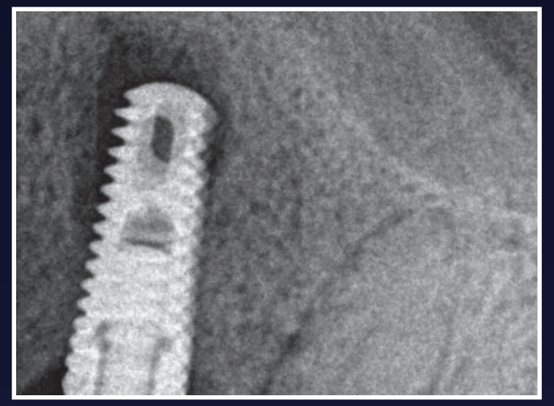

2. A periapical radiograph revealed a radiolucent lesion involving the apical portion of the implant fixture. The diagnosis was Retrograde Peri-implantitis

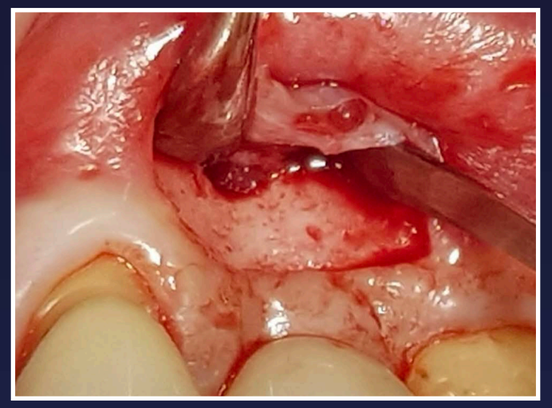

3. A semilunar incision starting at the mucogingival junction was made and a mucoperiosteal flap raised to locate the site of the lesion in relation to the buccal plate. Soft tissue invagination from the flap into the defect site was observed

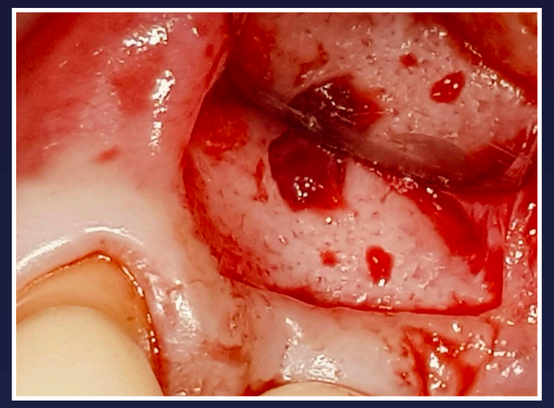

4. Flap elevation was completed and the defect exposed

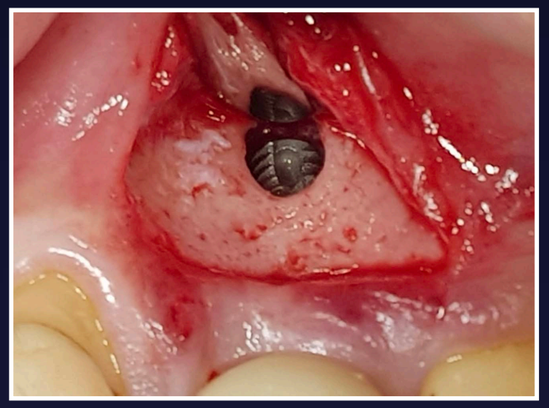

5. The defect was degranulated with titanium gracey curettes



6. Mechanical debridement of the implant surface was done with an air-abrasive device. This was followed by chemical disinfection with a 0.2% chlorhexidine solution



7. Bleeding was controlled at the defect site prior to grafting



8. Hydrated EthOss® Bone Graft biphasic synthetic graft was placed into the defect. The material was then dried for 5 minutes. Once the graft stabilized, the flap was repositioned and secured with 5/0 ptfe sutures. Post-op healing was uneventful

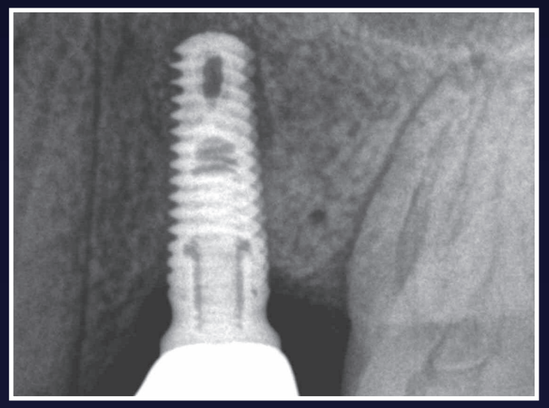

9. Periapical radiograph taken at 3 months post-op shows resolution of the lesion and complete defect fill

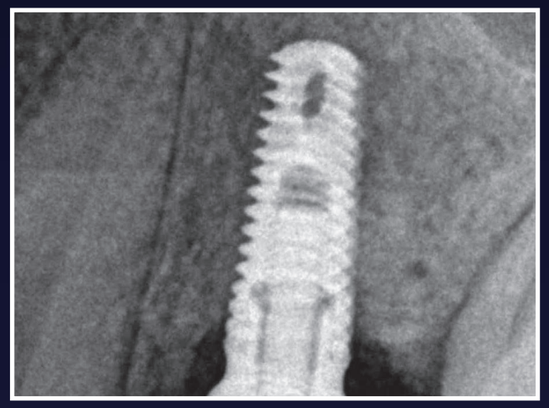

10. Periapical radiograph taken at 6 months post-op show a stable result and improved appearance of the regenerated bone

Peri-implantitis with infra-bony defect

PATIENT BACKGROUND

61 year old female
Non-smoker

The patient presented with peri-implantitis associated with an infra-bony defect around the implant site.

Following diagnosis, surgical access was achieved via full-thickness flap elevation. Thorough thermo-mechanical debridement of the defect was performed, followed by implant surface decontamination using hydrogen peroxide. EthOss® Bone Graft was placed to support osteoconduction and defect regeneration. A tension-free primary closure was achieved to optimise healing.

Post-operative clinical and radiographic follow-up demonstrated resolution of inflammation and evidence of bone regeneration.



Dr Hussein Asaria

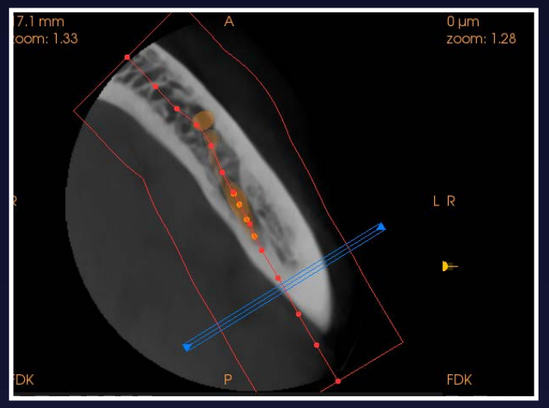

3. Planning

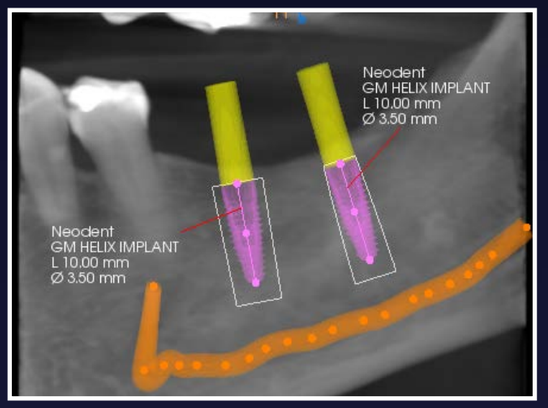

4. Planning

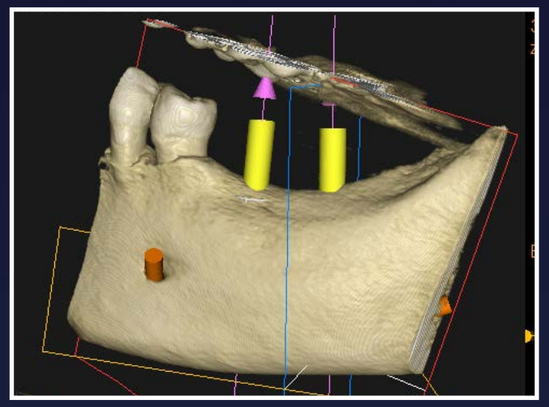

5. Planning

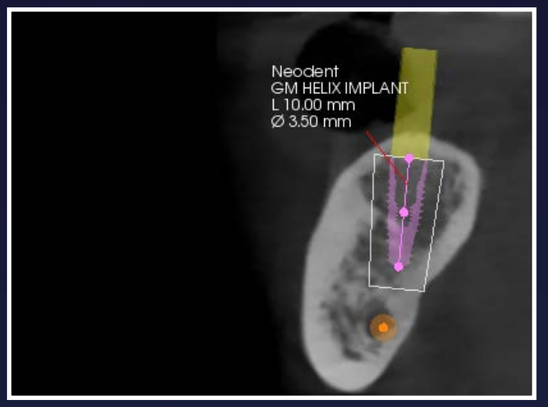

6. Planning



1. Pre-op soft tissue



2. Pre-op soft tissue

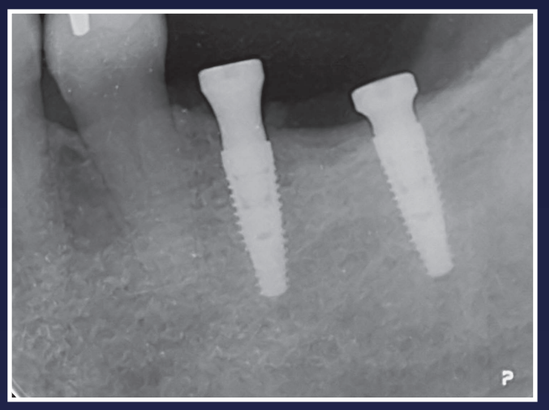

7. Radiograph at implant placement



8. Radiograph at impression

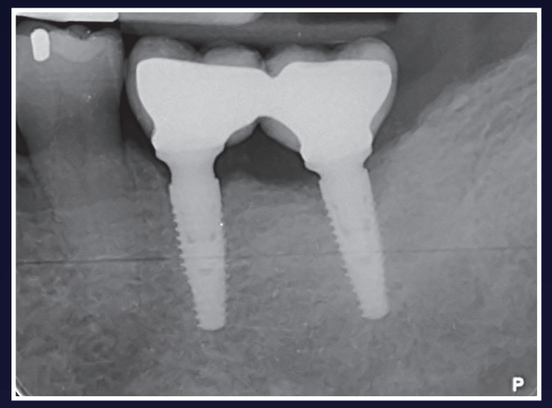

9. Radiograph at fit



10. Soft tissue at fit



11. Soft tissue at fit



12. Peri-implant defect

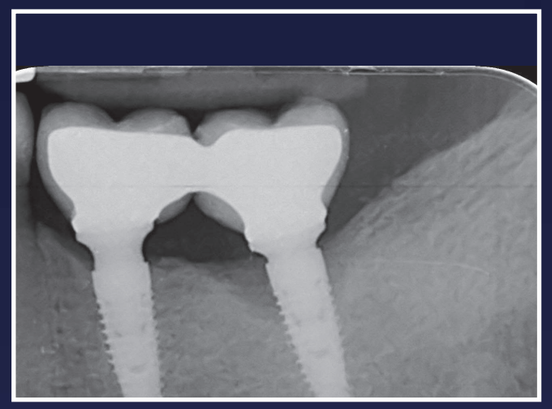

13. Bone loss around LL7



14. Bridge removed



15. Multi unit abutment removed

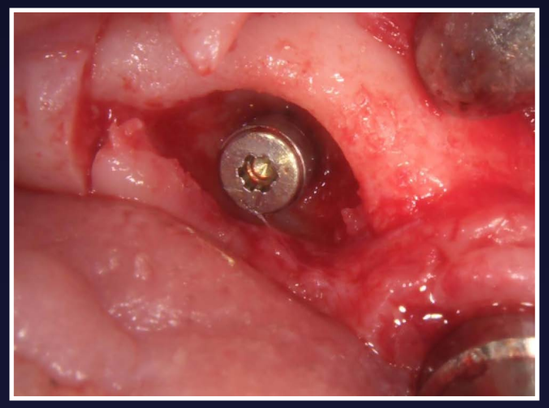

16. Flap raised and defected cleaned manually



17. Surface decontaminated with Hydrogen Peroxide

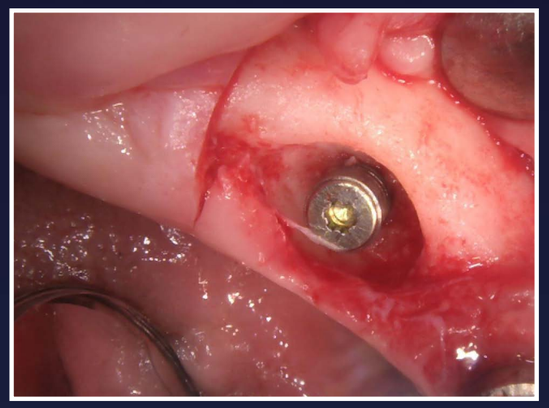

18. Bone and surface cleaned decontaminated

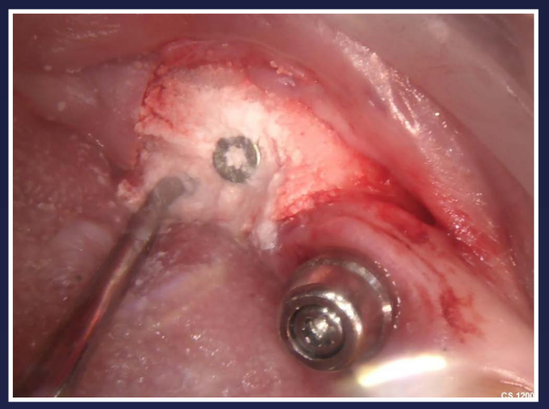

19. Defect filled with EthOss® Bone Graft

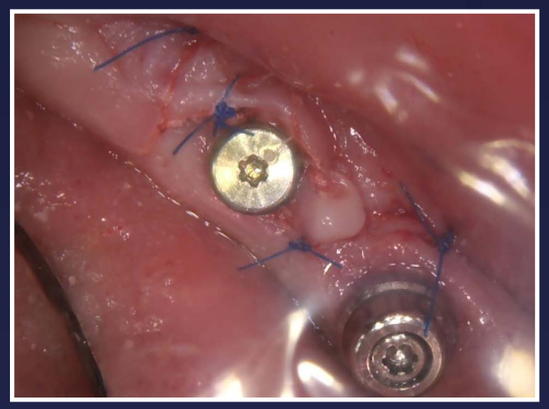

20. Healing abutment placed and sutured

04

Peri-implantitis with infra-bony defect



21. Re-assessment 4 months later

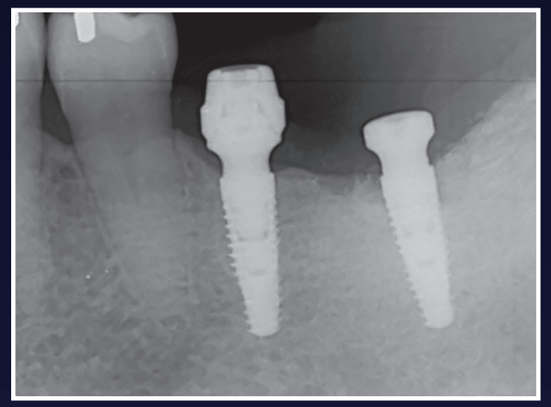

22. Radiograph - 4 months post-op

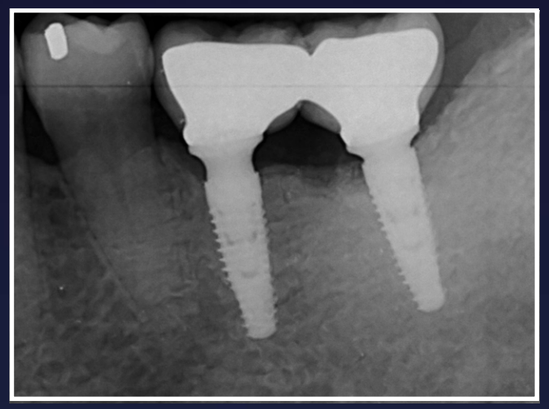

23. Radiograph at refit - 10 months post-op



24. Review - 2 years post-op

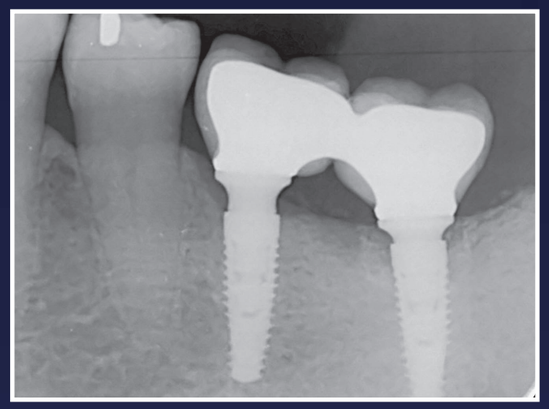

25. Review - 2 years post-op

Peri-implant complication due to incorrect healing screw

PATIENT BACKGROUND

42 year old male
Non-smoker

The patient was referred three months post-surgery following incorrect use of a healing screw, resulting in peri-implant complications.

The site was accessed through a full thickness periosteal flap, the site grafted with EthOss® Bone Graft, and the implant later restored with a final crown.

Radiographic and clinical review at one year confirmed stable peri-implant tissues and bone levels.



Dr Karol Badeja

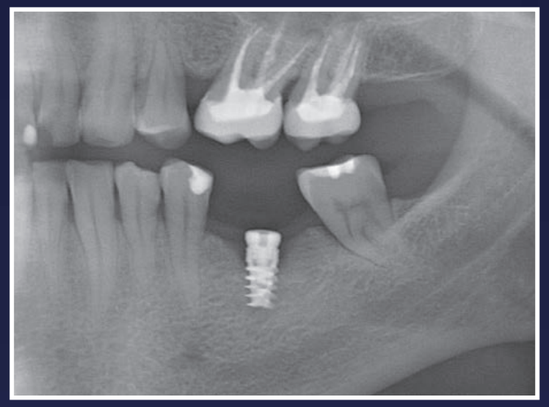

1. 3 month after surgical procedure. Patient was referred from another clinic. Incorrectly used healing screw



2. View after screw removed

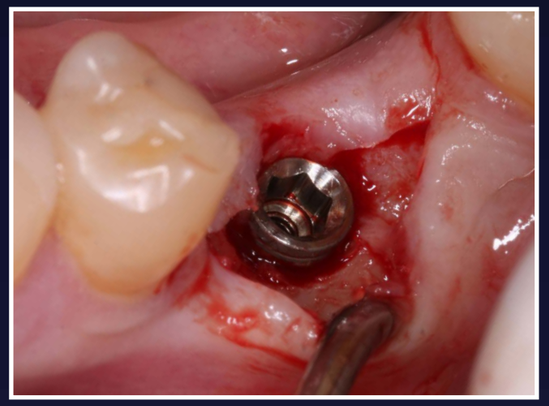

3. Access widened - defect visible



4. Defect grafted with EthOss® Bone Graft



5. The procedure ends with screwing in the final crown

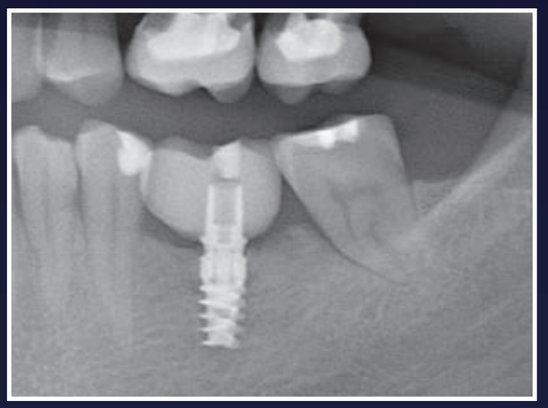

6. Post-op radiograph



7. Radiograph - 6 months



8. 1 year post-op

Periodontal Regeneration

A Biological Approach to Tooth Preservation

Across this chapter, we present a range of cases, from isolated angular defects to complex presentations involving systemic risk factors and furcation involvement. Each case demonstrates a consistent principle:

When biology is respected and stability is achieved, regeneration becomes predictable.

These cases are not intended to represent ideal scenarios, but real clinical situations where preservation was chosen over replacement.

Ultimately, the goal is not just to manage a disease, it is to regenerate restoring structure, function, long-term stability through resorbable materials that allow true bone regeneration.

Dr. Stuart Kilner

Head of Education



With special thanks to all our contributors

Dr Peter Fairbairn

Dr Alessandro Zussino

Dr Ayman El-Kashty

Dr Nabil Benabadji

Dr Stuart Kilner

LR5 Perio regeneration of bone loss

PATIENT BACKGROUND

58 year old female
Non-smoker
Receiving oral bisphosphonates

Patient was referred for an implant but had a preference to keep their tooth.

Presented with grade 3 mobility and a 9mm distal pocket on the LR5. The patient saw the Endodontist who confirmed the tooth was vital, with no perio-endo lesion present, so treated as a perio lesion.

A flap was raised and the distal area aggressively degranulated. 0.5cc EthOss bone graft material was then placed, dried in place with a sterile gauze and the site was closed with Coreflon PTFE sutures. For an additional layer of protection and the help stabilise the clot, the site was covered with BloodStop haemostatic matrix, forming a gel barrier over the site.

The patient returned at 1 year and 2 years post surgery, where probing pocket depth was reduced to 3-4mm (with no bleeding upon probing). The site appears stable and the case has now been successfully treated for over 3 years.



Dr Peter Fairbairn



1. Tooth LR5 - probing distal pocket depth of 9mm, angular bone loss, grade 3 mobile



2. Radiograph - defect prior to grafting



3. Flap raised, defect clearly visible



4. Site aggressively degranulated with EthOss® Degranulation Burs



5. Grafted with EthOss® Bone Graft material



6. Radiograph - at surgery. 0.5cc of EthOss Bone Graft material placed into defect

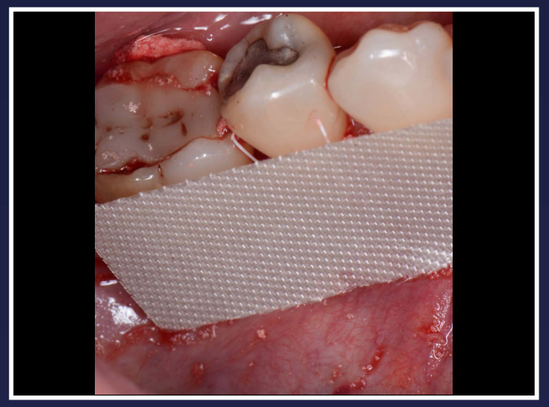

7. Sutured closed and covered with BloodStop haemostatic matrix



8. BloodStop forms a gel barrier over the site

LR5 Perio regeneration of bone loss



9. Review - 1 year post-op, site appears stable



10. Review - 2 years post-op, site appears stable



11. Review - 2 years post-op, probing pocket reduction to 3-4mm, no bleeding on probing



12. Radiograph - 2 years post-op

ethOss Grow Stronger

Management of a deep infrabony defect

PATIENT BACKGROUND

39 year old male
Non-smoker

Documented history of rheumatoid arthritis and diabetes.

After treatment and retreatment with non-surgical approach, the decision was made to treat this deep pocket surgically.

A flap was raised, exposing the defect which was degranulated prior to graft placement. The site was then sutured closed. 5 months later the patient returned, with probing pocket depth reduced from 12mm initially to 3mm, the site is now stable.

KEY TAKEAWAY

Regeneration of a deep defect with stable outcome and pocket reduction at 5 months.



Dr Alessandro Zussino

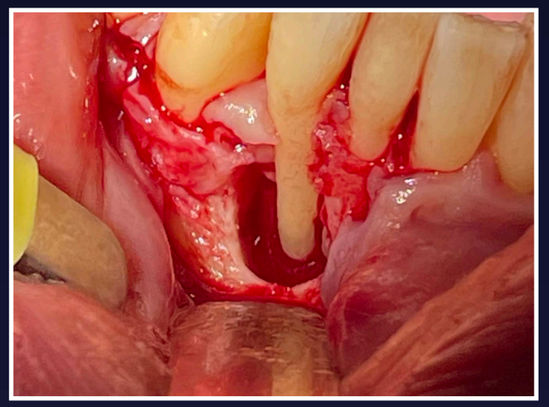

3. Exposing the defect after degranulation

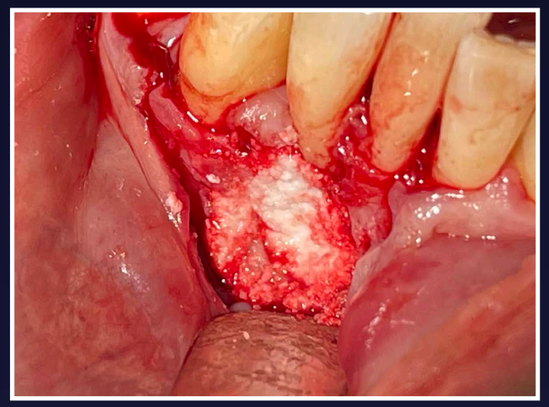

4. First EthOss® Bone Graft



5. Second EthOss Bone Graft

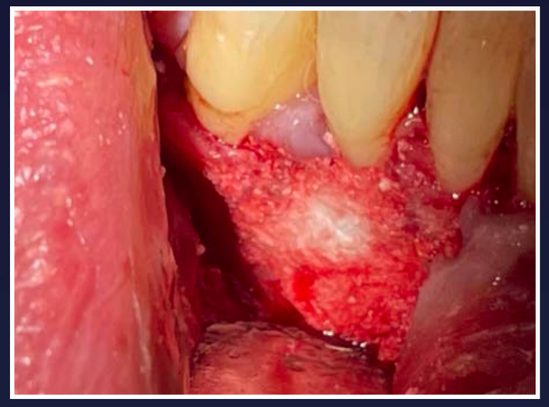

6. Set EthOss Bone Graft



1. Pre-op probing - 12mm

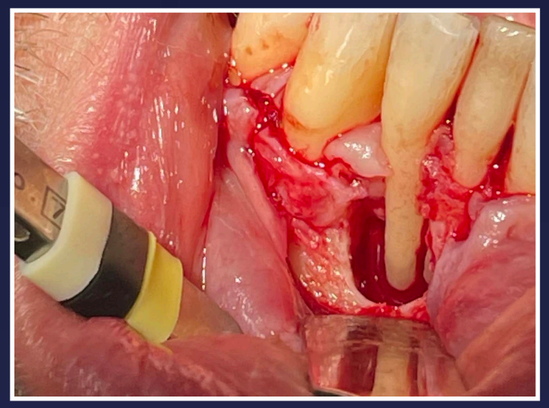

2. Papillae preservation flap



7. Healing - 5 months post-op



8. Distal probing - 3mm

Management of a deep infrabony defect



9. Mesial probing - 3mm



10. 3D reconstruction from a CBCT at healing

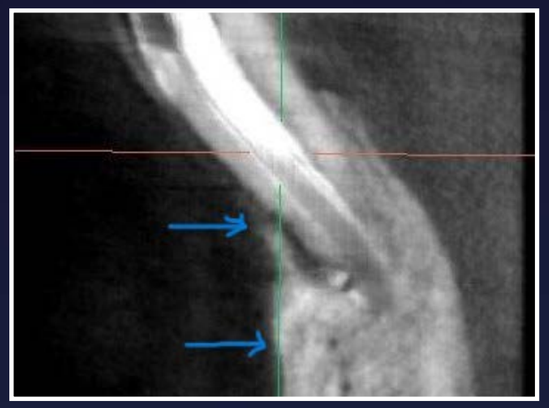

11. Cross from the same CBCT with the bone levels before and after

ethOss Grow Stronger

Vertical defect regeneration with CTG Wall Technique (Zucchelli Approach)

PATIENT BACKGROUND

53 year old female
Non-smoker
Prescribed anti-depressants

Patient was referred for an extraction of the upper left premolar due to continuous pain and a deep periodontal pocket but the patient preferred to try save the tooth.

Patient presented with a Grade I mobility, 12mm distal pocket and 10mm mesial pocket. We referred the patient to the endodontist to make RCT firstly as there was a perio-endo lesion. A full thickness modified Kirkland's flap was raised to expose the defect and the pockets were cleaned effectively using hand scalers, gracey currettes and bone scalers. An EDTA gel was applied on the root surface for 3 minutes to ensure an adequate smear layer removal and root surface conditioning prior to EthOss Bone Graft application.

Free gingival graft was harvested from the palate and deepithelized to get DEFGG and sutured to the inner flap surface using 5/0 vicryl resorbable suture to provide adequate blood clot stabilisation and to enhance the gingival phenotype at the recipient site (CTG Wall Technique) introduced by Prof. Dr. Giovanni Zuchelli. 1cc of EthOss Bone Graft was placed at the defect and dried in place with a sterile gauze. The flap was then sutured using 5/0 polypropylene non-resorbable sutures.

The patient returned for a review at 1 year and 2 years post-op where the probing pocket depth was redcued to 2/3mm with no bleeding on probing.



Dr Ayman El-Kashty



1. After modified Kirkland's flap reflection showing massive amount of granulation tissues surrounding the tooth



2. After granulation tissues debridement showing the vertical bone defect



3. Vertical bone defect mesially and distally following granulation tissues debridement



4. After root surface planning to ensure adequate removal of the microorganisms from superficial layer of cementum

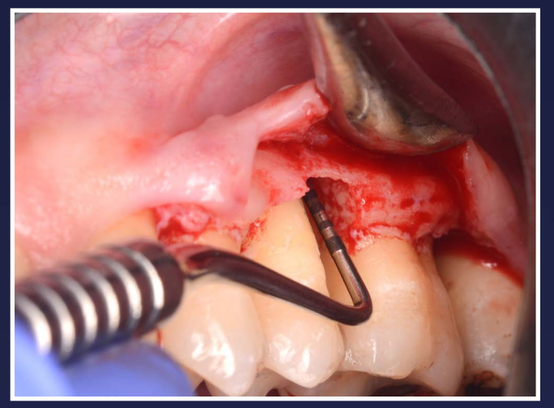

5. Probing depth following degranulation tissues procedures



6. DEFGG suturing to the inner aspect of the flap to give the CTG wall technique (zuccheli technique)

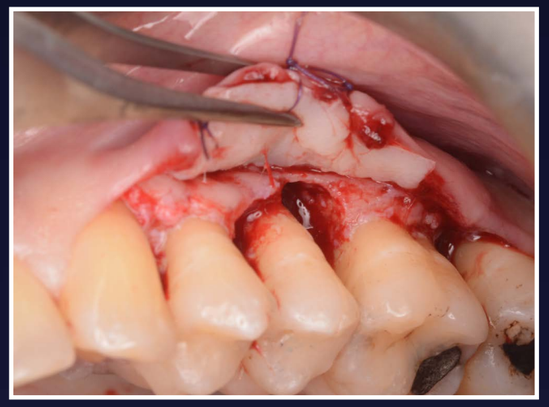

7. After suturing of the DEFGG

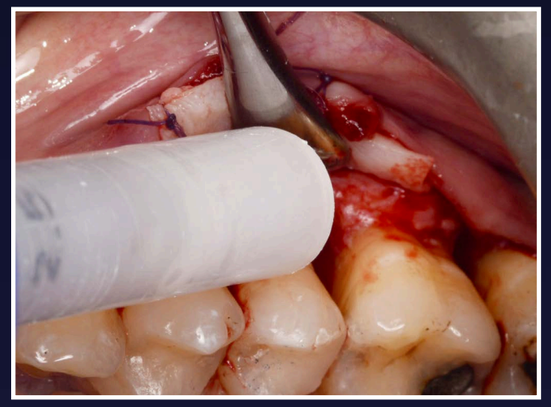

8. EthOss® Bone Graft application

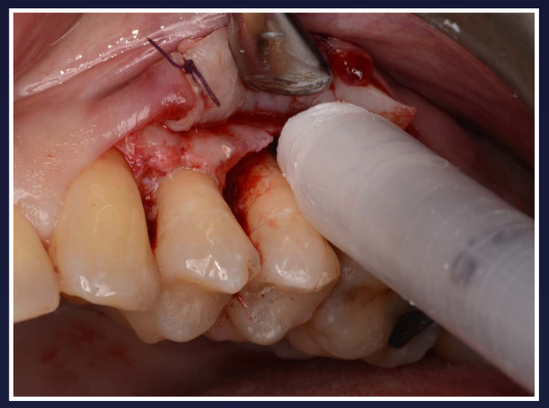

9. EthOss Bone Graft at the vertical bone defect mesially and distally

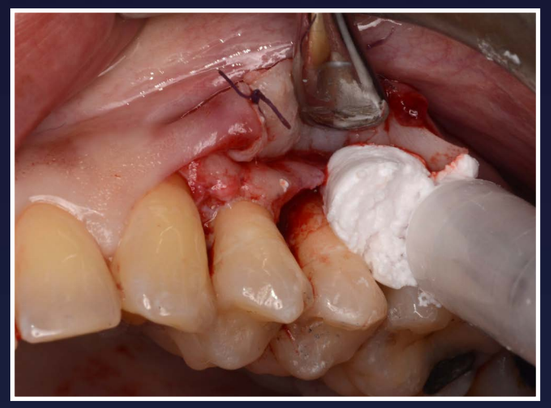

10. Application of EthOss Bone Graft



11. Adaptation of EthOss Bone Graft into the defect



12. After EthOss Bone Graft application



13. Suturing



14. The palatal donor site for FGG closure using composite resin template



15. Review - 6 months post-op

ethOss Grow Stronger_

Grade II furcation defect - regenerative management

PATIENT BACKGROUND

48 year old male
Non-smoker

Patient presented with a bifucation infection and grade 2 periodontitis with 10mm probing pocket depth.

The patient preference was to attempt to save the tooth, therefore surgery was undertaken to treat the defect. A flap was raised, the defect thoroughly degranulated and EthOss bone graft material placed. The material was allowed to harden for 5 minutes before the site was sutured closed. The site was then treated with Bluem oral gel to improve healing.

The 1 year review shows the case is now stable and the bone levels have recovered.



Dr Nabil Benabadji

KEY TAKEAWAY

Contained furcation defects can regenerate effectively with a stable scaffold and proper debridement.



1. Pre-op site assessment

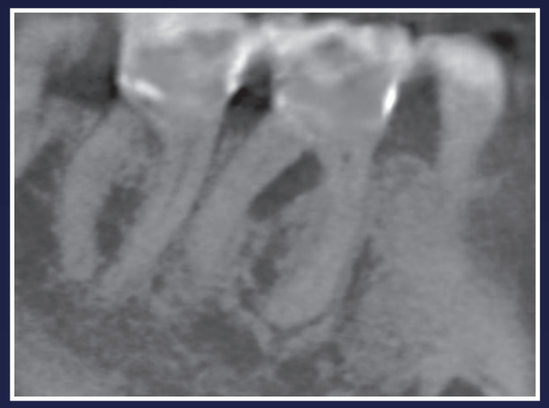

2. Pre-op radiograph

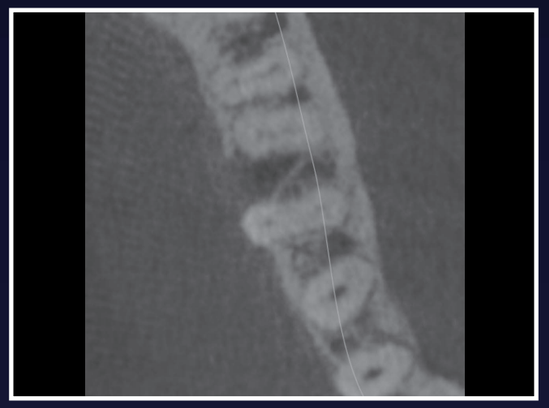

3. Pre-op radiograph

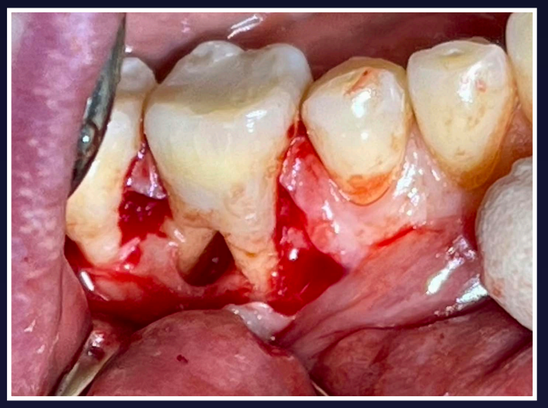

4. Post degranulation



5. Grafting with EthOss® Bone Graft



6. Grafting with EthOss Bone Graft



7. Sutured closed



8. Post-op

Grade II furcation defect - regenerative management



9. Post-op with blue®m



10. Post-op radiograph



11. Review - 1 year post-op



12. Review - 1 year post-op

ethOss Grow Stronger

Localised severe Periodontitis - deep angular defect

PATIENT BACKGROUND

39 year old male
Non-smoker

8-10 mm distal pocket so solid angular bone loss. Degranulated and grafted with EthOss® Bone Graft.

The UL2 was very mobile and we initially considered extraction, however due to lockdown and social distancing rules in the UK at the time, we were unable to place any temporary aesthetically. The final result at 4 months shows a significant improvement which will hopefully improve over time.

KEY TAKEAWAY

Even mobile teeth with deep angular defects can be stabilised with regenerative therapy when defect morphology is favourable.



Dr Stuart Kilner



1. Initial situation



2. Distal 9mm pocket

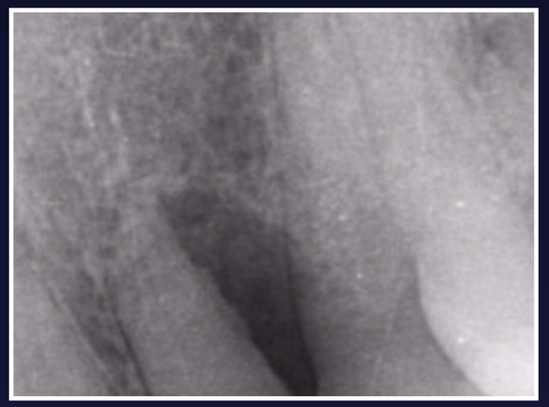

3. Radiographic view of defect

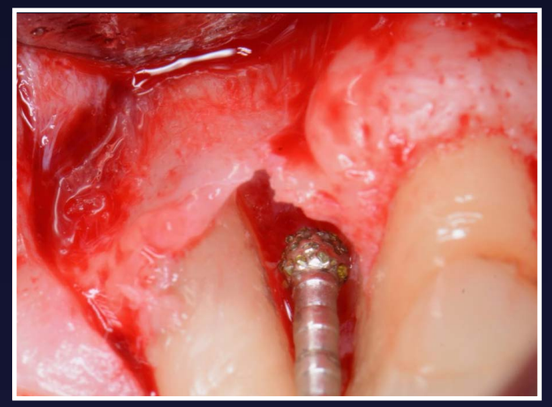

4. Degranulation

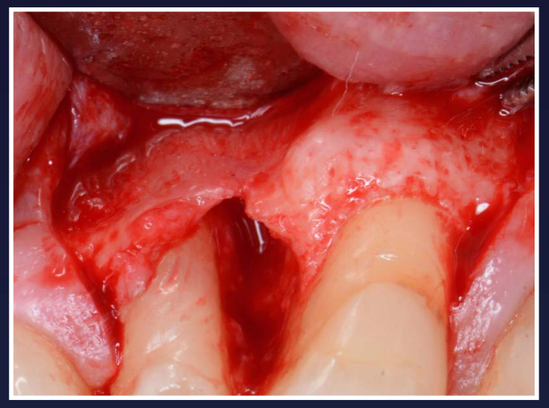

5. Cleaned site



6. Grafted with 0.25cc of EthOss® Bone Graft material

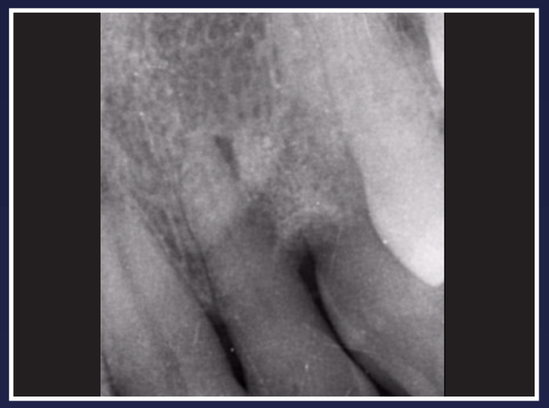

7. Radiograph immediately post-op



8. Sutured with PTFE

05

Localised severe Periodontitis - deep angular defect



9. 4 months post-op

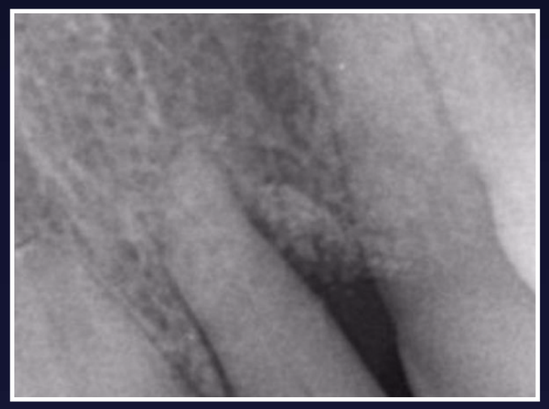

10. 4 months post-op - graft is being replaced by host bone

Cysts

Clinical applications of EthOss Bone Graft in cystic defect regeneration

Cystic lesions of the jaws are a common finding in clinical practice and can range from small incidental radiographic observations to extensive defects associated with infection, bone destruction and significant restorative challenges. Traditionally, these defects have often been viewed as complex cases requiring multiple interventions before definitive rehabilitation could be considered.

As our understanding of regenerative biology has progressed, so too has our approach to these defects. The objective is no longer simply to occupy a space or maintain volume, but rather to create an environment capable of supporting predictable host bone regeneration and long-term tissue stability. Increasingly, the focus has shifted from augmentation towards regeneration — restoring tissue in a way that promotes natural healing and supports future function.

EthOss® was developed around this same philosophy; simplifying regenerative procedures whilst encouraging replacement with the patient's own vital bone rather than long-term graft retention. The cases presented throughout this chapter demonstrate how regenerative principles can be applied across a range of cystic defects, from relatively straightforward lesions through to extensive defects requiring staged management and complex rehabilitation.

Within these cases you will see varying surgical approaches including enucleation, decompression, endodontic microsurgery and implant rehabilitation. While treatment protocols differ, the principles remain consistent: careful diagnosis, atraumatic surgery, defect management and respect for the biology of healing.

Importantly, this collection is not intended to present a single solution for every case. Instead, it demonstrates how understanding regenerative principles can simplify treatment and provide clinicians with predictable outcomes even in challenging situations.

I would like to sincerely thank all contributing clinicians for sharing their experience and clinical work. It is through collaboration and the sharing of knowledge that we continue to improve our understanding and ultimately improve outcomes for our patients.

I hope this collection provides practical insight and useful learning that can be translated into your own clinical practice.

Dr. Stuart Kilner

Head of Education





With special thanks to all our contributors

Dr. Peter Fairbairn

Dr. Tomas Stumbrys

Dr. Jakub Kwiatek

Dr. Gareth Jones

Dr. Ayman El Kashty

Dr. Andrei Mostovei

Dr Strisca Stanislav

Radicular cyst with staged implant rehabilitation

PATIENT BACKGROUND

Long-standing radicular cyst associated with UL6. Histology confirmed an encapsulated lesion allowing complete removal.

SUMMARY OF TREATMENT

Complete cyst enucleation followed by EthOss® Bone Graft placement and staged implant treatment.

KEY TAKEAWAYS

- Complete cyst removal simplifies regeneration
- Soft tissue management is critical
- Stable hard and soft tissue outcomes achieved



Dr Peter Fairbairn



1. Long term cyst apical to the UL6 (molar)



2. Cyst removal - encapsulated cyst so clean removal

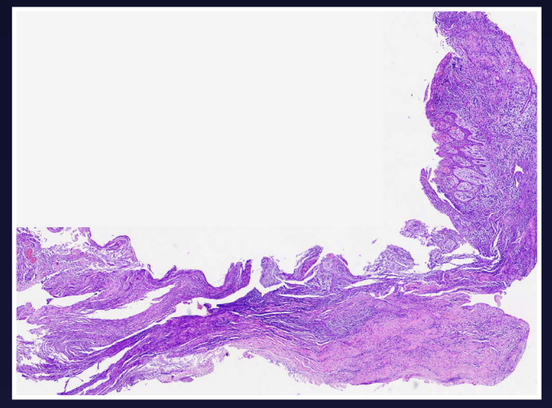

3. Histology of the cyst shows it to be radicular

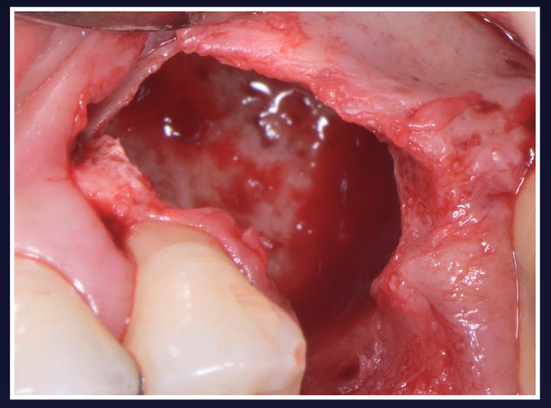

4. Clean site, no degranulation necessary

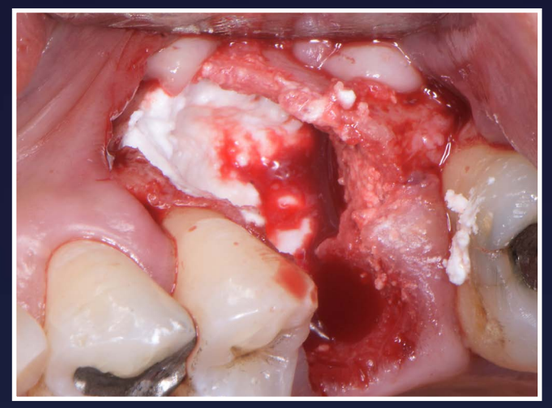

5. Initial placement of 1cc of EthOss® Bone Graft, another was added but underfilled



6. Sutured closed - under filling of site to allow soft tissue healing



7. Post-op radiograph indicates could have been filled more

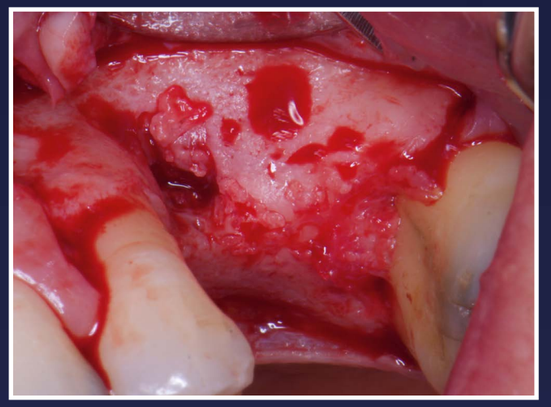

8. Site regeneration. Small soft tissue in-growth next to second premolar

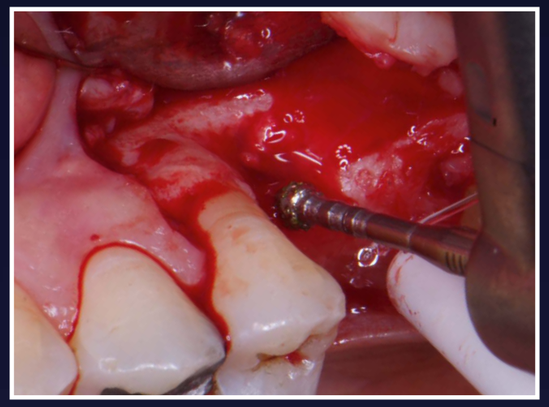

8. Degranulation of the soft tissue “tag”

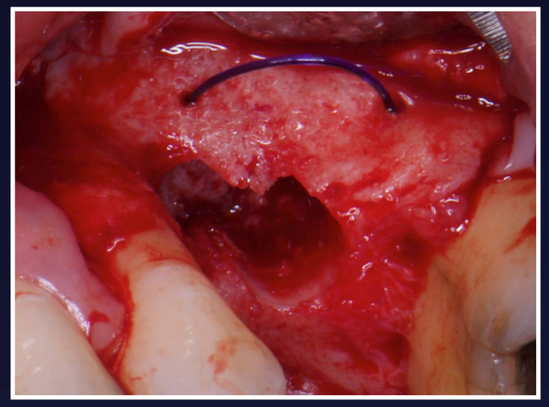

9. Soft tissue degranulated and osteotomy done and PDS 2.0 suture tent placed

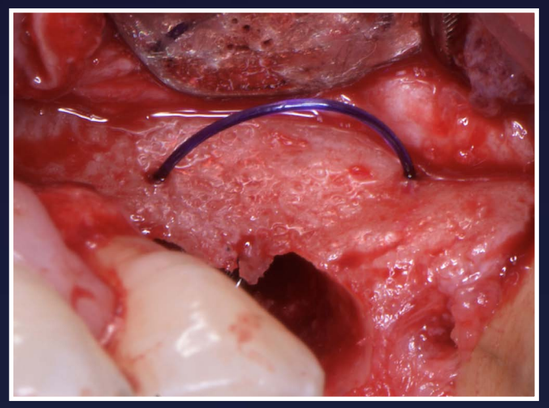

10. Placed and stable

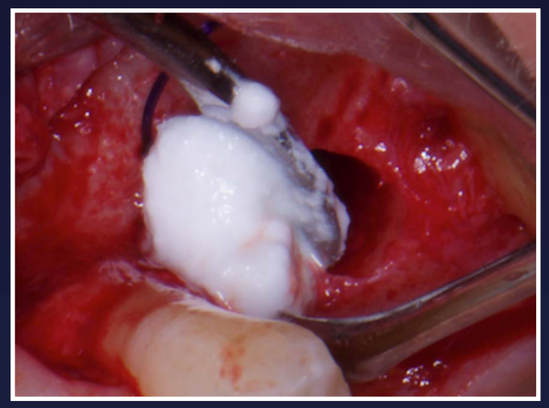

11. Wetter EthOss Bone Graft material being placed into degranulated site

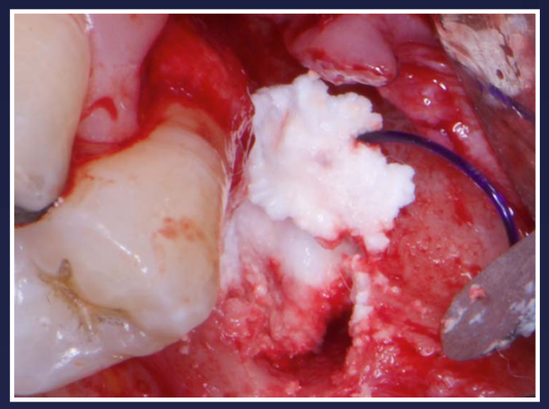

12. Wetter EthOss Bone Graft material being placed into degranulated site

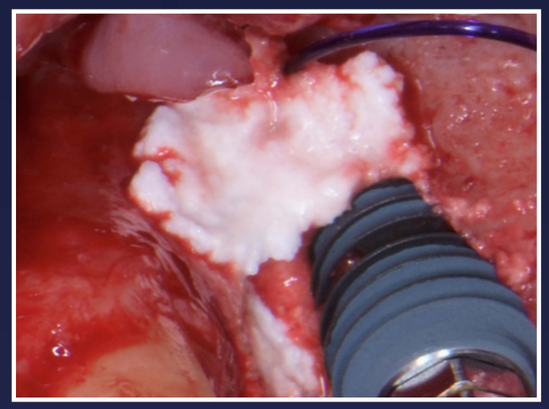

13. AnyRidge® implant 4.5mm placed into osteotomy with wet EthOss Bone Graft

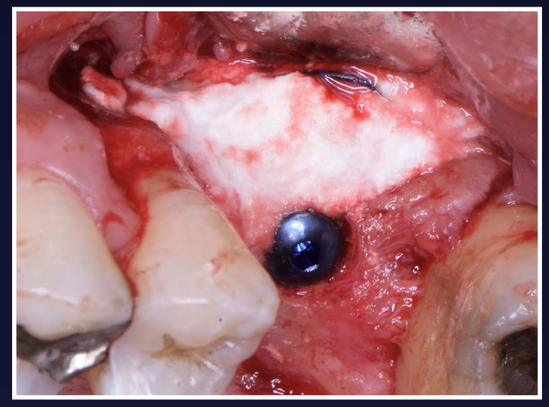

14. Buccal tented, site filled. May have benefited from a customised healing cap

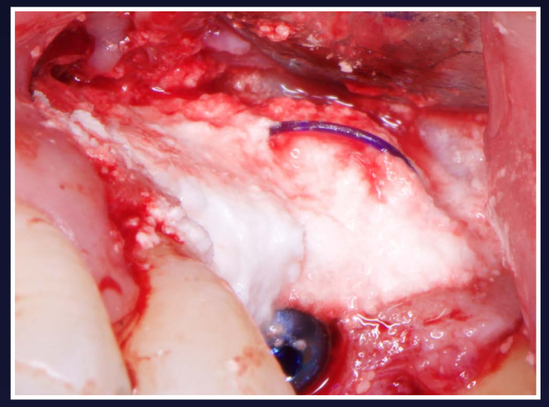

15. Set EthOss Bone Graft and the suture holding the soft tissue away

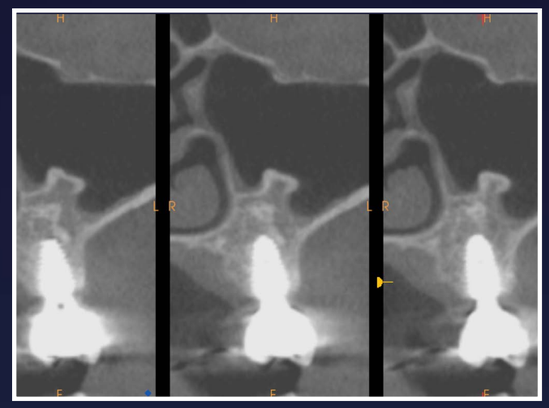

16. CBCT 2 years post-op shows the cyst regeneration and buccal plate



17. 2 years post-op - showing nice hard and soft tissue stability



18. 2 years post-op - showing hard and soft tissue stability

Immediate implant placement following radicular cyst removal

PATIENT BACKGROUND

49-year-old female, non-smoker, with multiple missing teeth and a cystic lesion associated with UL2

SUMMARY OF TREATMENT

Extraction, immediate implant placement and cyst removal via an apical access window with EthOss Bone Graft placement.

KEY TAKEAWAYS

- Immediate implant placement may be possible after cyst removal
- Careful debridement is essential
- Predictable regenerative outcomes achieved



Dr Tomas Stumbrys



3. Pre-op

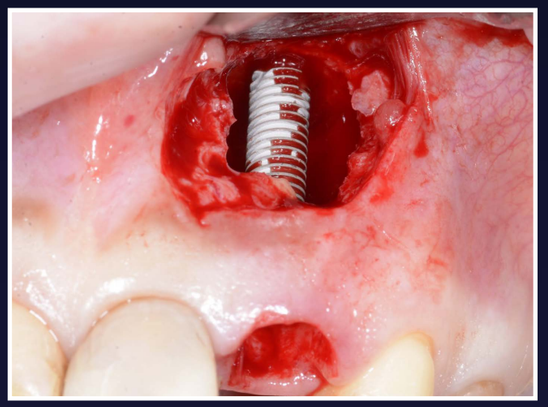

4. After cyst removal

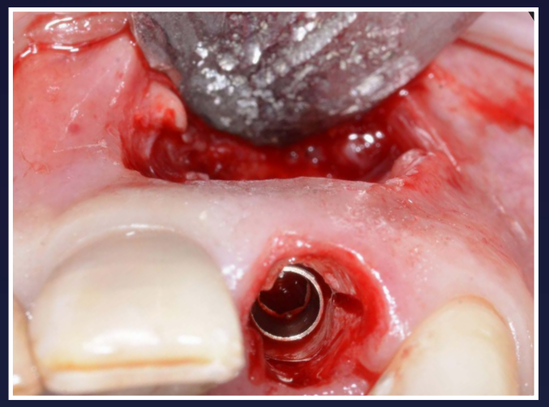

5. Occlusal view



6. Cyst filled with EthOss® Bone Graft



1. Radiograph - pre-op. View UL2



2. Radiograph - pre-op. View UL2



7. 4 months post-op

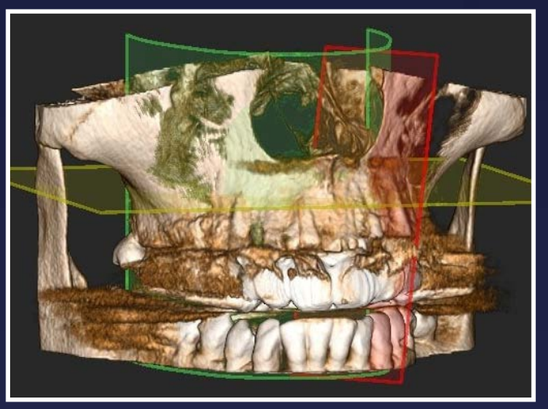

8. 4 months post-op

02

Immediate implant placement following radicular cyst removal



9. 4 months post-op. Further restorative treatment completed



10. 4 months post-op

Immediate implant placement following radicular cyst removal

PATIENT BACKGROUND

37-year-old female, non-smoker, presenting with extensive maxillary bone loss and significant buccal deficiency. CBCT revealed an extensive bone defect at the planned implant sites, not communicating with the maxillary sinus. The most significant bone loss was observed on the buccal aspect.

SUMMARY OF TREATMENT

Cyst enucleation, implant placement and regeneration using EthOss Bone Graft.

KEY TAKEAWAYS

- Large defects do not exclude implant treatment
- Digital planning improves accuracy
- Long-term tissue stability demonstrated



Dr Jakub Kwiatek



1. Pre-op CBCT scan (maxilla – panoramic view)

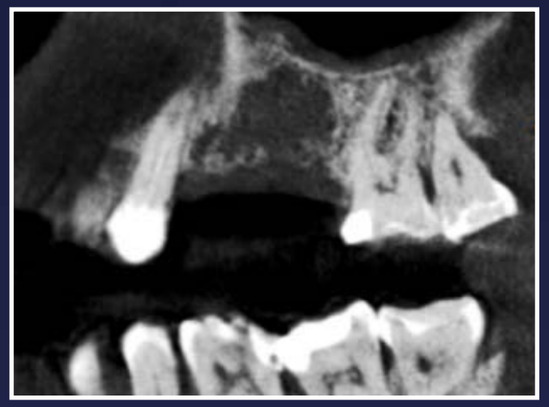

2. Pre-op CBCT showing a bone lesion at the planned implant sites - sagittal view

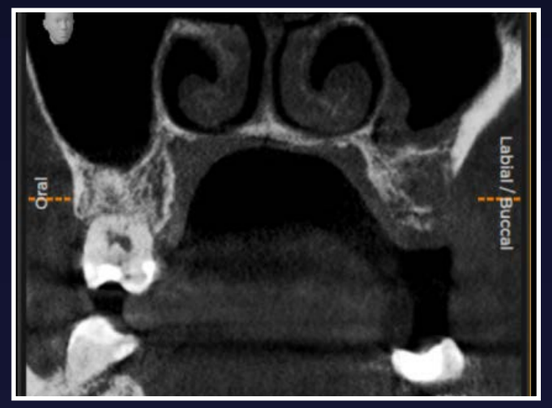

3. Pre-op CBCT - bone lesion at the planned implant sites - coronal view



4. Pre-op CBCT showing a bone lesion at the planned implant sites - axial view



5. Initial clinical situation

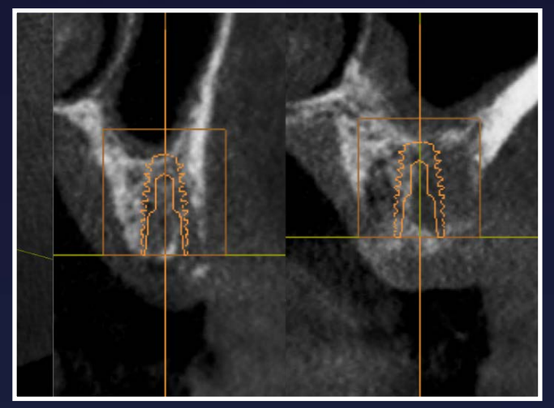

6. Digital implant planning for UL5 and UL6

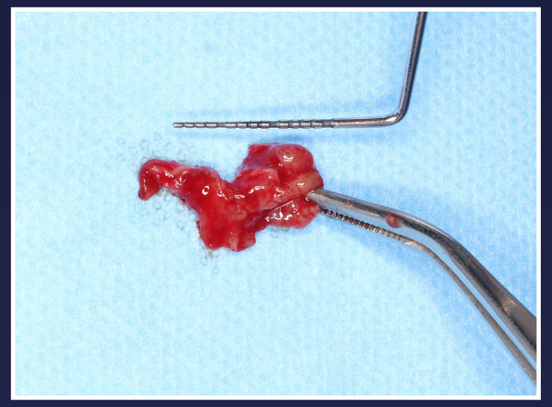

7. Removal of cyst



8. Intra-operative placement of positioning guides at the planned implant sites UL5 and UL6

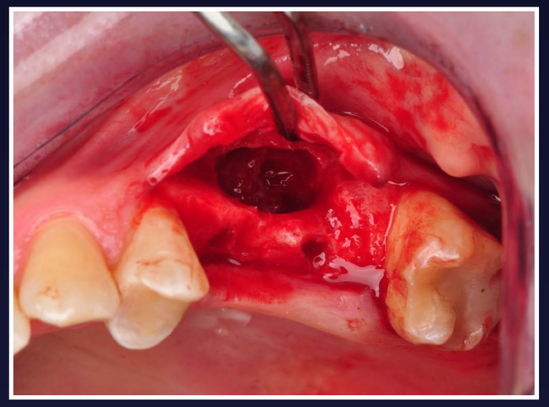

9. Intra-operative view after elevation of a full-thickness mucoperiosteal flap

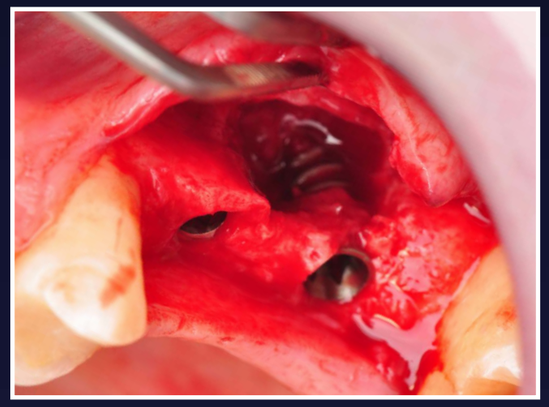

10. Extensive bone defect observed in the implantation area

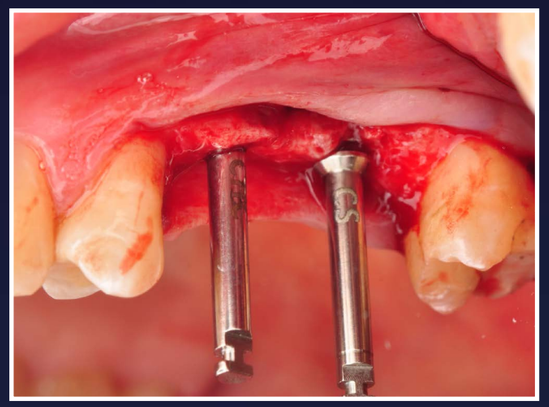

11. Intraoperative stage – verification of optimal implant positions



12. Pre-augmentation view with EthOss® Bone Graft



13. Post-augmentation view with EthOss Bone Graft



14. Post-augmentation view - tension-free closure of the mucoperiosteal flap

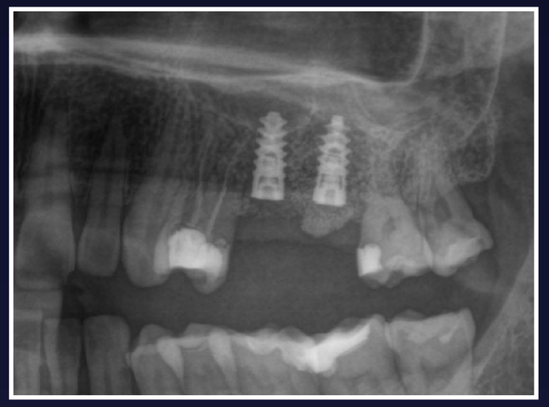

15. Post-op periapical radiograph confirming correct implant positioning



16. Placement of screw-retained full-ceramic crowns on implants UL5 and UL6



17. Panoramic follow-up radiograph - 2 years post-op



18. Aesthetic outcome - 2 years post-op



19. Aesthetic outcome - 2 years post-op



20. CBCT scan - 6 years post-op

Large radicular cyst associated with iatrogenic root perforation

PATIENT BACKGROUND

73-year-old male, non-smoker, with controlled hypertension taking amlodipine. A large radicular cyst associated with UR3 developed following iatrogenic root perforation during post crown preparation.

SUMMARY OF TREATMENT

The cyst was enucleated via a buccal approach with apicectomy and endodontic treatment of adjacent teeth. The resulting defect was grafted using EthOss® Bone Graft followed by delayed implant placement and restoration.

KEY TAKEAWAYS

- Large cystic defects involving adjacent teeth can often be managed while preserving surrounding dentition
- Combined surgical and endodontic treatment may be required
- EthOss Bone Graft enabled regeneration of extensive defects without the need for additional membranes
- Stable clinical and radiographic outcomes were observed after two years



Dr Gareth Jones



1. Pre-op



2. Pre-op periapical

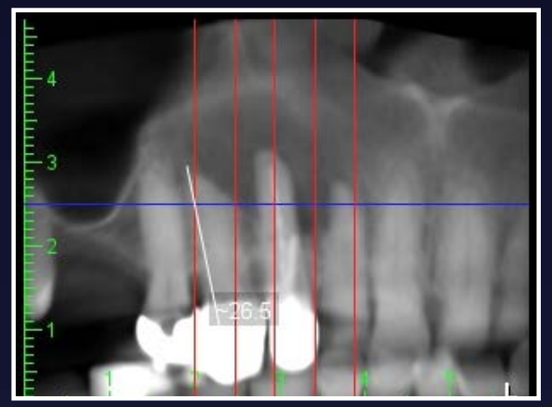

3. Panoramic view from CBCT pre-op

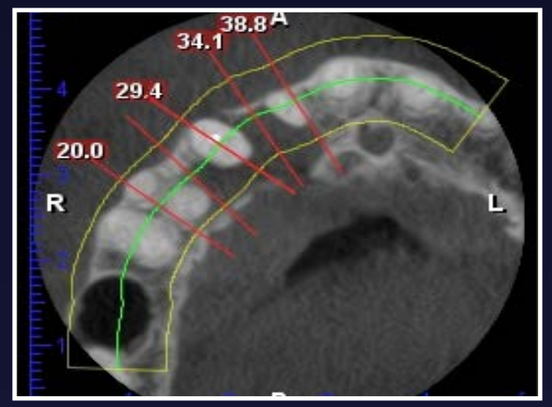

4. Pre-op - axial view

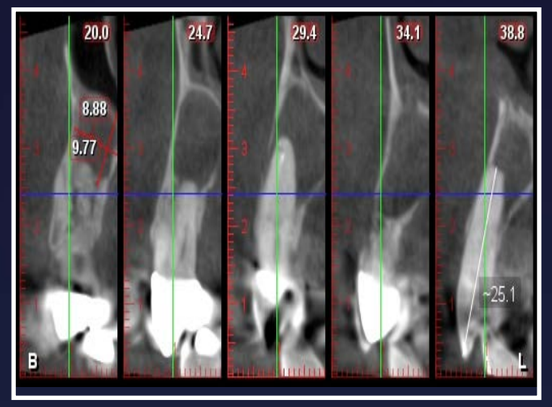

5. CT slice showing cyst up to nasal floor, leaving buccal and palatal cortical plates



6. Extracted canine with root perforation



7. Enucleated cyst

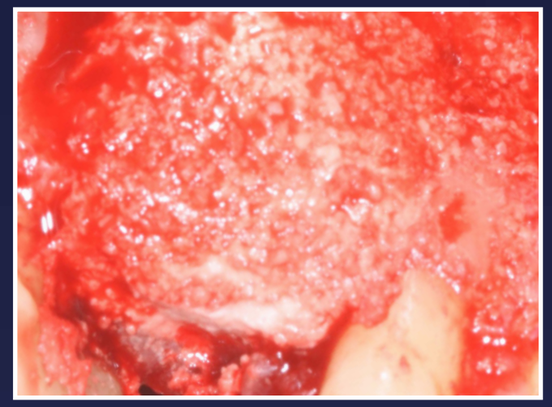

8. Defect grafted with EthOss® Bone Graft

04

Large radicular cyst associated with iatrogenic root perforation



9. PA at implant placement



10. Final restoration

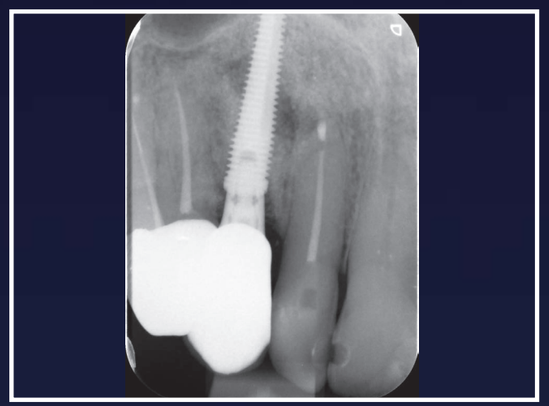

11. Review - 1 year post-op



12. Review - 2 years post-op

ethOss Grow Stronger

Periapical cyst managed with endodontic microsurgery

PATIENT BACKGROUND

40 year old female
Non-smoker
Taking Calcium channel blockers

Patient was referred due to pain in the upper right central, lateral incisors and canine due to a cystic lesion involving the apical thirds, diagnosed by CBCT and periapical radiographs.

The patient was referred for root canal treatment of the affected teeth.

A full-thickness mucoperiosteal flap was raised to avoid gingival recession, the buccal bone related to cyst was removed, the cystic lesion was fully enucleated, and apicectomy with retrograde MTA filling was performed.

The defect was grafted with 1cc EthOss® without the need of a membrane, and the flap was sutured with 5/0 polypropylene. Follow-ups showed excellent gingival health.



Dr Ayman El Kashty



1. Initial situation



2. Initial incision using 15c blade



3. Incision at the mucogingival junction to avoid gingival recession



4. After full thickness mucoperiosteal flap reflection

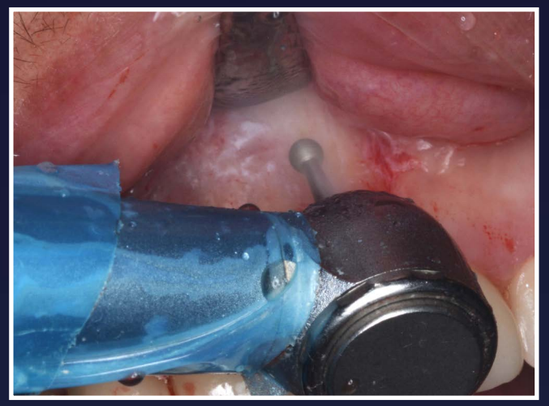

5. Exposure of the cystic lesion at the apical thirds of the involved roots



6. Cystic lesion eneculation



7. Full lesion debridement



8. Cystic lining

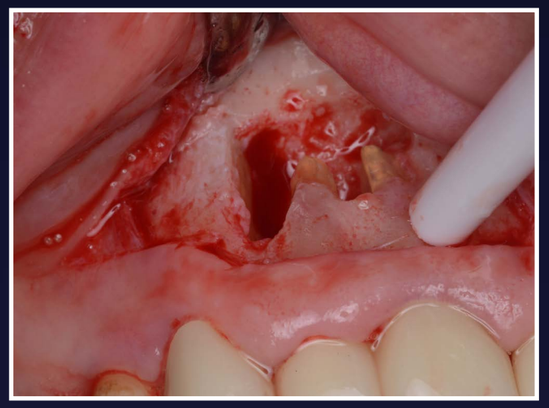

9. After complete removal of the cystic lesion and irrigation

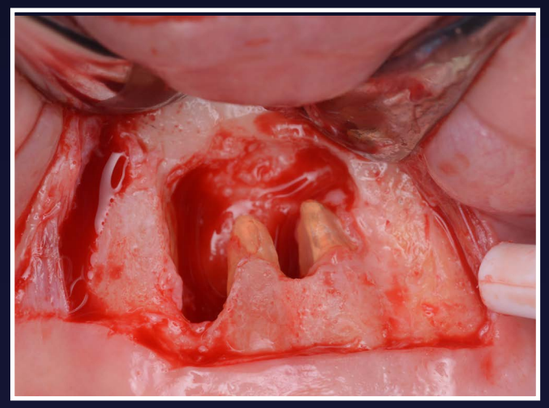

10. Post apicectomy and retrograde filling using putty MTA



11. EthOss® Bone Graft being placed



12. EthOss Bone Graft drying in situ



13. After complete adaption



14. EthOss Bone Graft in situ



15. Before flap closure



16. After suturing using 5/0 polypropylene sutures



17. Review - 2 weeks post-op



18. Review - 2 years post-op

Large posterior maxillary cyst managed with decompression and regeneration

PATIENT BACKGROUND

36-year-old male, non-smoker, with an asymptomatic extensive periapical lesion involving the posterior maxilla discovered during routine examination.

SUMMARY OF TREATMENT

Initial decompression was performed using a custom 3D-printed device to reduce lesion size prior to definitive cystectomy. Following cyst removal, EthOss Bone Graft was used to reconstruct the defect before delayed implant placement and restoration.

KEY TAKEAWAYS

- Staged decompression can reduce surgical morbidity in large cystic lesions
- Custom 3D-printed devices can facilitate conservative defect management
- EthOss Bone Graft supported regeneration of extensive defects including sinus floor reconstruction
- Long-term imaging demonstrated complete bone regeneration and implant stability





Dr Andrei Mostovei and Dr Strisca Stanislav

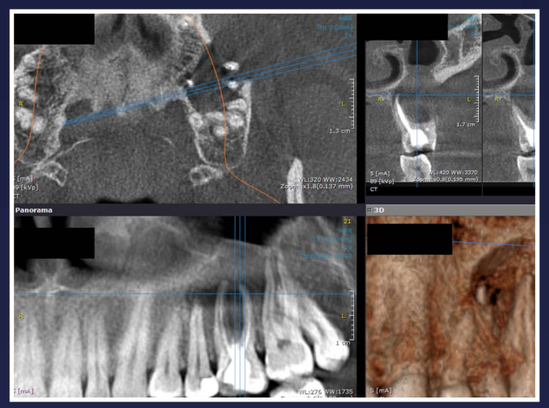

1. Pre-op CBCT shows extensive periapical lesion involving roots of second premolar and all three molars and sinus floor

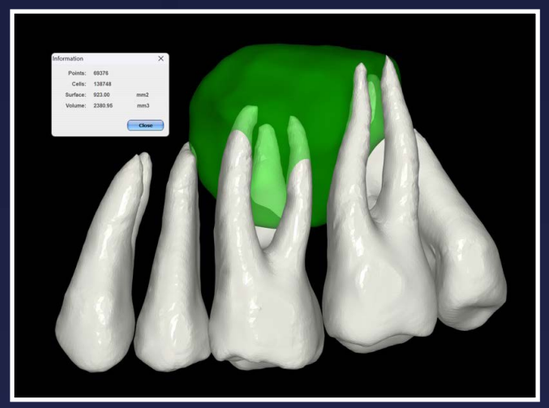

2. Virtual modelling of the cyst for decompression 3D printed device planning



3. 2 week post extraction illustrates infected cyst. Tooth extraction performed to drain the purulent collection

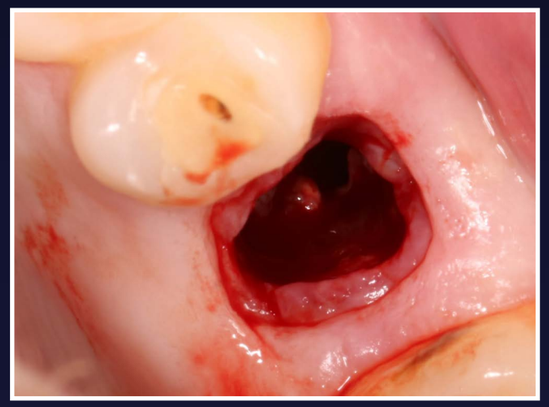

4. Excision of the granulation tissue

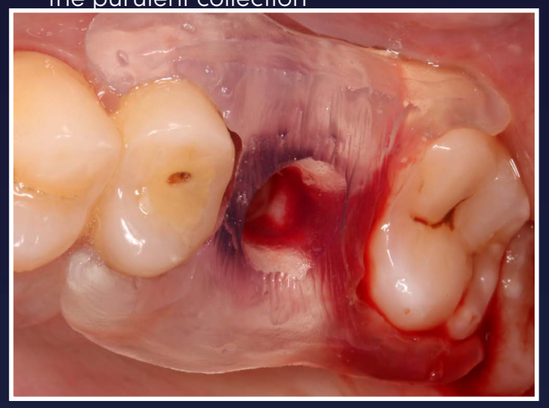

5. Application of 3D printed decompression device for daily irrigation

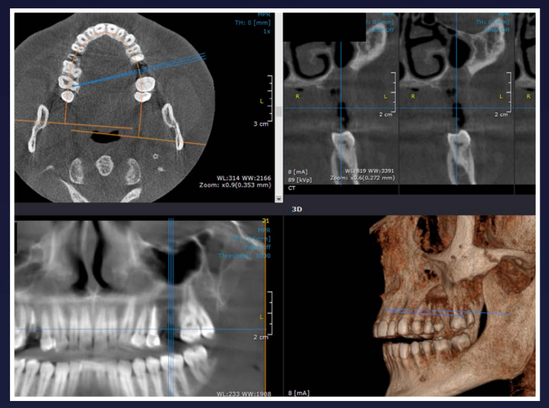

6. CBCT - 4 months post-op, illustrates decrease of cyst



7. Intra-oral view after 4 months of wearing decompression device

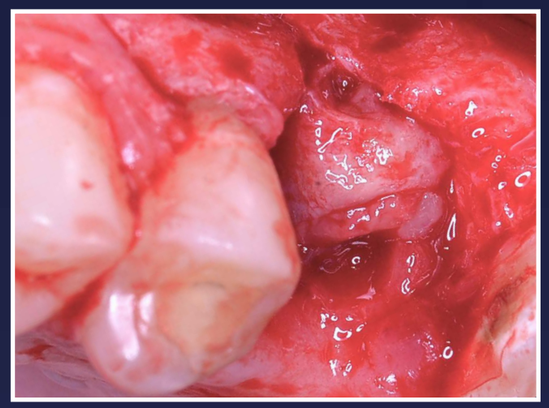

8. Muco-periosteal flap reflection for cystectomy

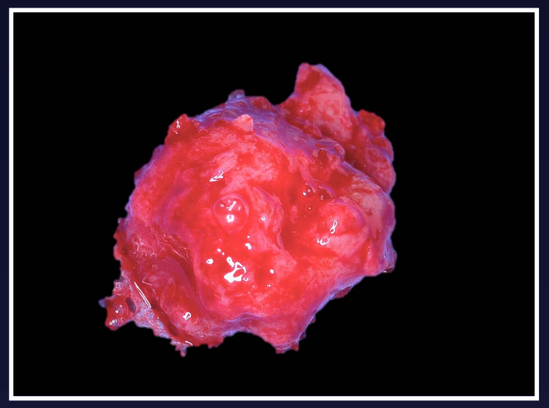

1. The aspect of the removed cyst

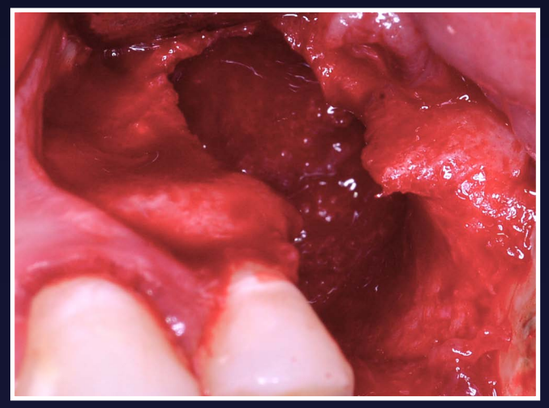

2. Post-cystectomy - new sinus floor formation without molar root involvement

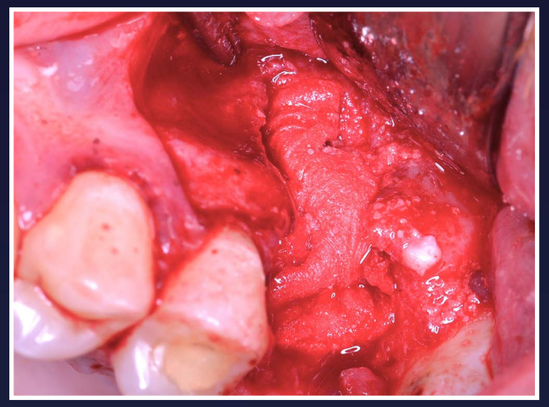

3. Intra-operative view of filled bone defect



4. Buccal bone reconstruction with EthOss® Bone Graft

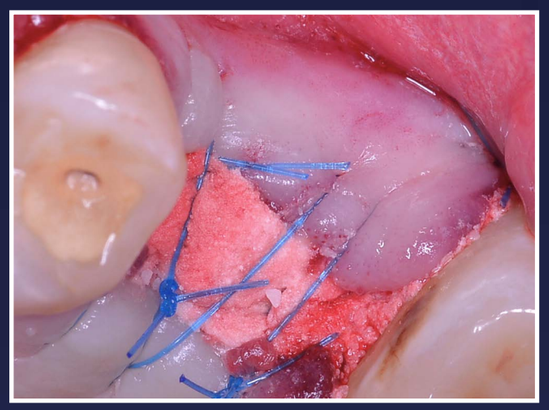

5. The aspect of the wound after suturing – the crestal exposed space was covered with collagen sponge for secondary intention healing



6. Review - 8 months post-op

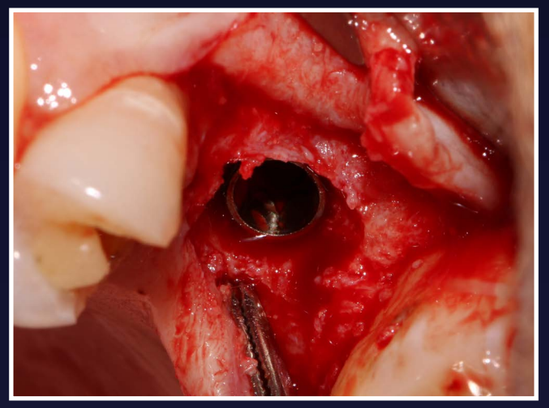

7. Implant placement into newly formed bone

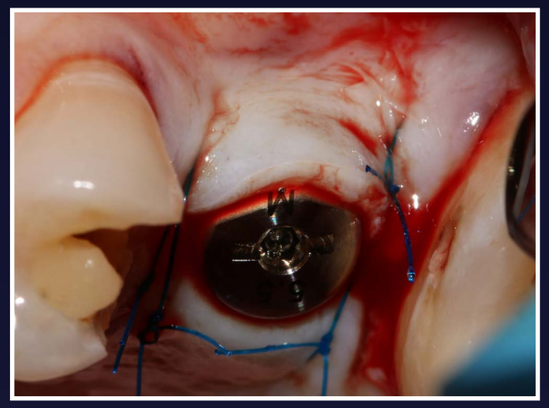

8. The aspect of healing abutment after wound suture

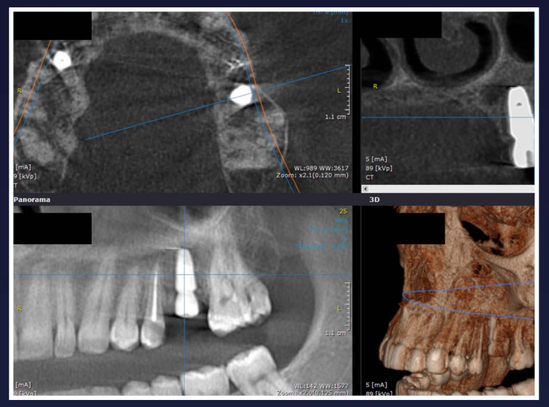

9. CBCT - 8 months post-op, good buccal cortical bone can be observed

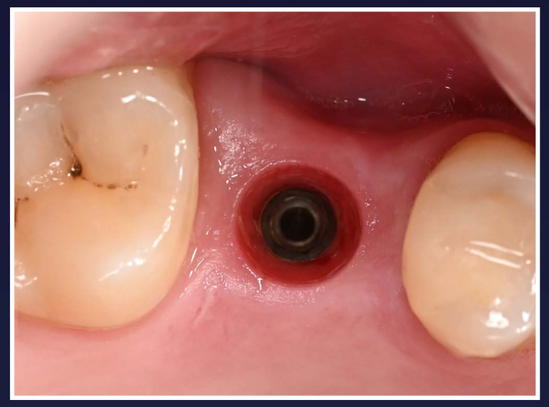

10. Peri-implant mucosa - no signs of inflammation or bleeding at the end of healing period



11. Fixation of screw-retained restoration



12. CBCT analysis after the prosthetic treatment shows a good bone healing around implant and complete bone regeneration at the level of molars as well as sinus floor

Advanced Surgical Techniques

Advanced surgical techniques allow clinicians to manage cases in which bone volume, anatomy or previous treatment makes conventional implant placement difficult. Success in these situations depends on careful diagnosis, sound biological principles and a surgical plan that protects the tissues throughout healing.

The cases in this chapter cover autotransplantation, staged ridge regeneration with customised titanium mesh, suture tenting complex full-arch rehabilitation and the push-in technique. Each clinician has adapted the treatment sequence to the anatomy and restorative goal while using EthOss® Bone Graft to support regeneration where additional bone was required.

Taken together, the cases show the value of thorough degranulation, stable graft containment, tension-free closure and structured post-operative review. I would like to thank the contributing clinicians for sharing their work and the clinical records that make this case collection possible.

Dr. Stuart Kilner

Head of Education



With special thanks to all our contributors

Dr. Bi Cheng

Dr. Nabil Benabadji

Dr. Moustafa Hijazi

Dr. Costa Nicolopoulos

Dr. Che Chao

Dr. Peter Fairbairn

Autotransplantation with buccal bone regeneration

PATIENT BACKGROUND

23-year-old male
Non-smoker

SUMMARY OF TREATMENT

A cracked tooth 36 was extracted and replaced by autotransplanting tooth 18, with the buccal contour regenerated using EthOss® Bone Graft. Retrograde endodontic preparation and filling were completed before the donor tooth was seated. Clinical and radiographic reviews were at 6 months and 1 year.

KEY TAKEAWAYS

- Autotransplantation can provide a biologic tooth-replacement option for young patients with a suitable donor tooth.
- Atraumatic donor-tooth handling and accurate recipient-site preparation are central to the surgery.
- Buccal bone regeneration supports restoration of the contour where a facial bone defect is present.
- Endodontic management and structured clinical and radiographic review are integral to outcome.



Dr Bi Cheng

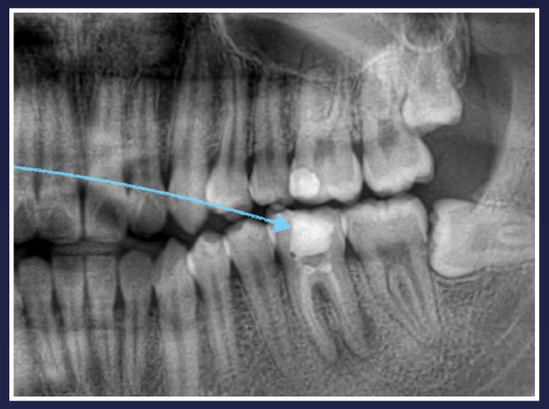

1. Pre-op radiograph showing tooth 36 (recipient site)



2. Pre-op clinical view of 18 donor tooth



3. Buccal bone defect at the recipient site

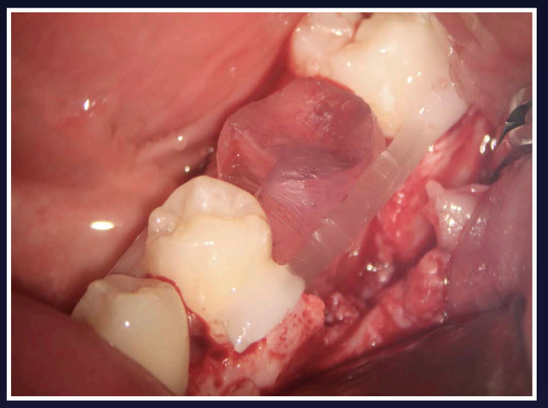

4. Attempt placement of resin tooth

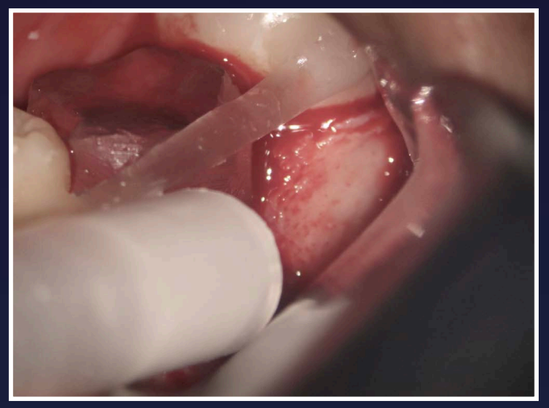

5. Buccal bone augmentation with EthOss® Bone Graft

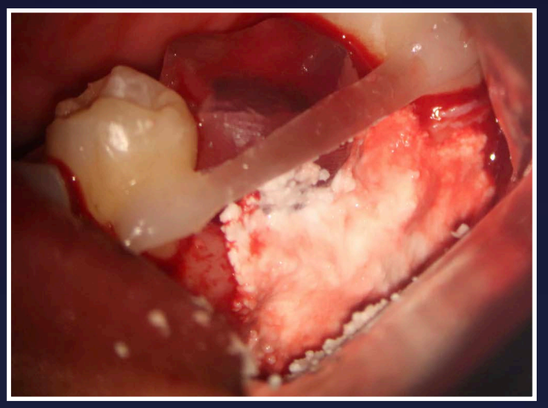

6. Placement of EthOss Bone Graft



7. Minimally invasive extraction of 18



8. Retrograde root canal preparation



9. Retrograde filling with bioceramic material



10. Autotransplantation completed

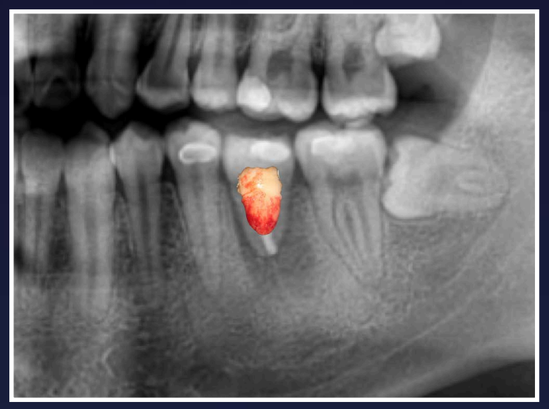

11. Post-op radiograph



12. Radiograph - 6 months post-op

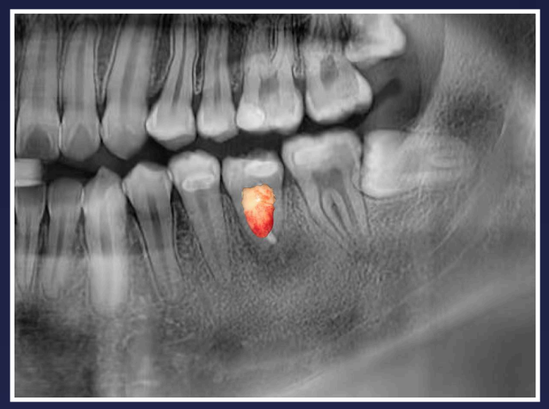

13. Radiograph - 1 year post-op



14. Radiograph - 1 year post-op

Autotransplantation with buccal bone regeneration



15. Clinical view - 1 year post-op

Staged ridge regeneration with customised titanium mesh

PATIENT BACKGROUND

61-year-old female
Smoker

SUMMARY OF TREATMENT

Tooth 46 had been missing for decades, and tooth 45 was extracted at another clinic in 2019. Both sites were regenerated in 2024 using a customised titanium mesh with EthOss® Bone Graft. The mesh was removed after three months and two Nobel Biocare implants were placed one month later. Following a three-month period, the implants were restored with two screw-retained single crowns.



Dr Nabil Benabadji

KEY TAKEAWAYS

- A customised titanium mesh maintained space during staged regeneration of long-standing deficient sites.
- Removing the mesh before implant placement allowed assessment of the regenerated ridge.
- The staged protocol separated ridge regeneration, implant placement and prosthetic loading.



1. Radiograph - initial situation

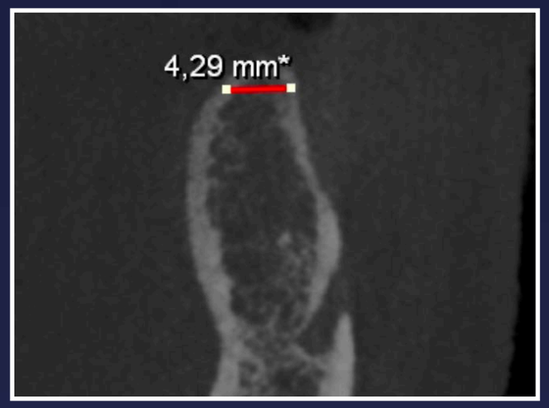

2. Radiograph - initial situation



3. EthOss® bone graft placement

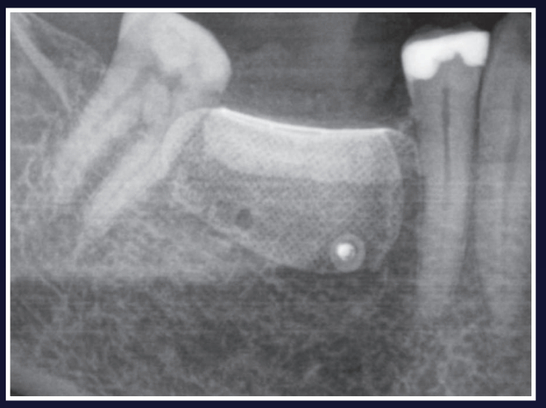

4. Customised titanium mesh in situ

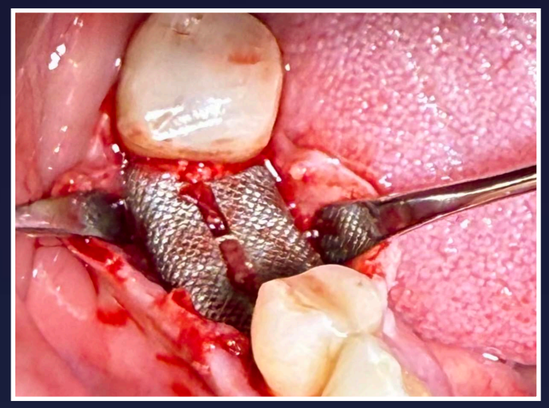

5. Mesh removal

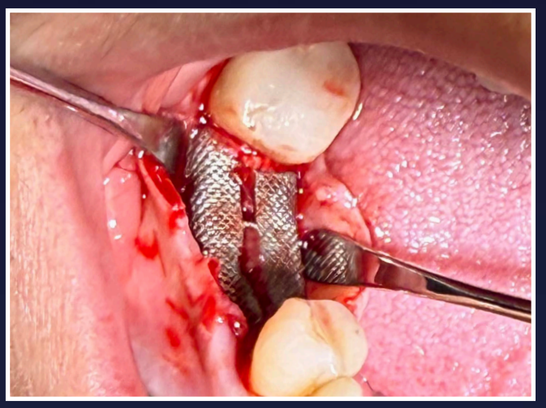

6. Mesh removal



7. Mesh removal

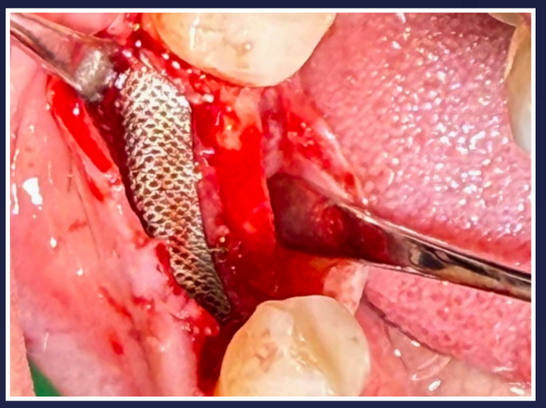

8. Mesh removal

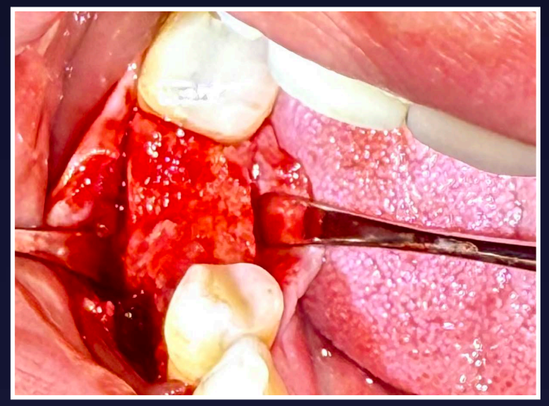

9. Post mesh removal



10. Post mesh removal



11. 1 month post mesh removal



12. 1 month post mesh removal

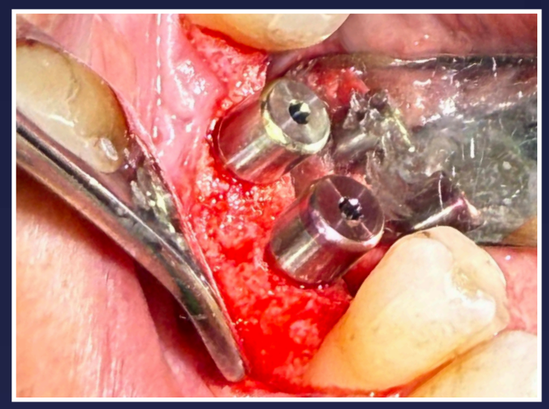

13. Implant placement

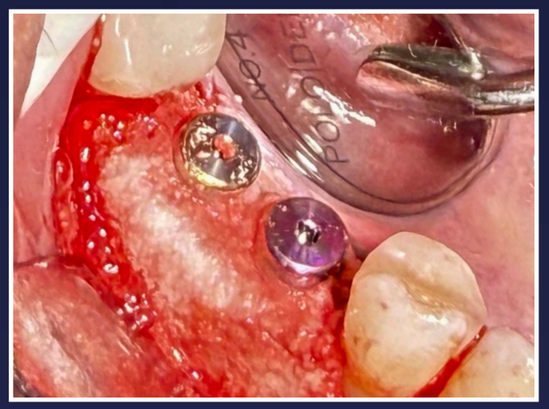

14. Layer technique with EthOss Bone Graft

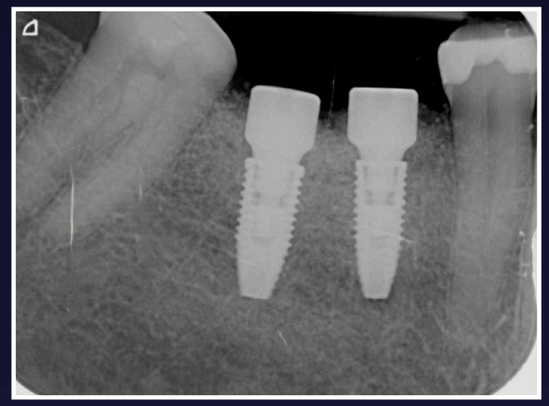

15. Radiograph - post-op



16. 3 months post implant placement

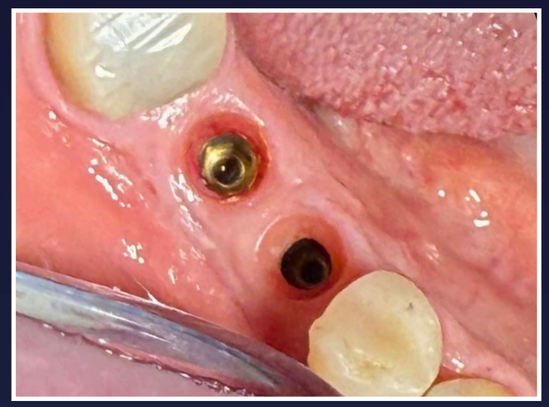

17. 3 months post implant placement



18. Radiograph - 3 months post implant placement



19. 1 year control



20. Radiograph - 1 year control

Staged ridge regeneration using a tenting suture technique

PATIENT BACKGROUND

The patient requested a fixed bridge in the left maxilla. Imaging identified a retained root at site 23 and advanced bone loss.

SUMMARY OF TREATMENT

Following removal of the retained root and defect preparation, regeneration of the left maxillary ridge was carried out with EthOss® Bone Graft. Resorbable PDS sutures were used as a tenting framework to maintain space and stabilise the graft. After healing, implants were placed at sites 23, 24 and 26 with additional EthOss to refine the crestal contour. The implants were subsequently exposed and assessed.



Dr Moustafa Hijazi

KEY TAKEAWAYS

- Resorbable tenting sutures can maintain space without permanent fixation hardware.
- Staged regeneration can create the ridge volume required for implant placement in a severe defect.
- Graft stability, passive closure and sufficient healing time are central to this approach.



1. OPG from referring dentist

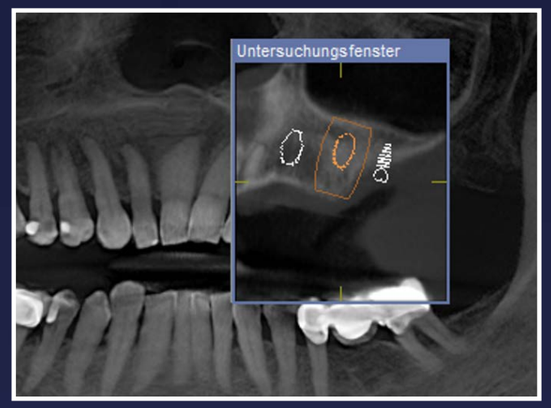

2. Initial situation CBCT

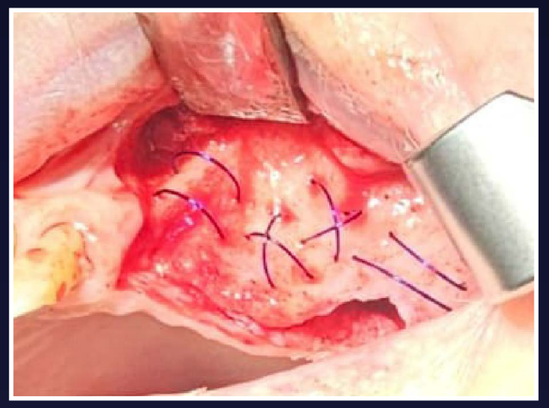

3. Tenting suture technique

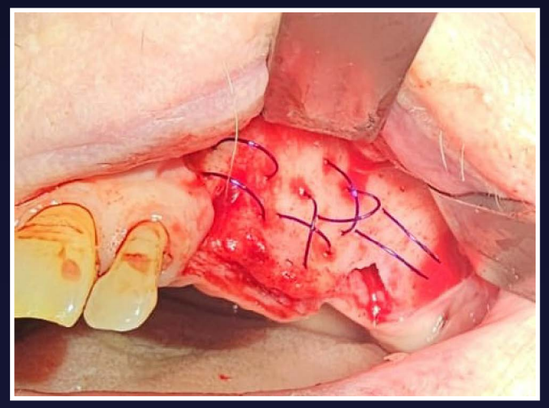

4. Tenting suture technique

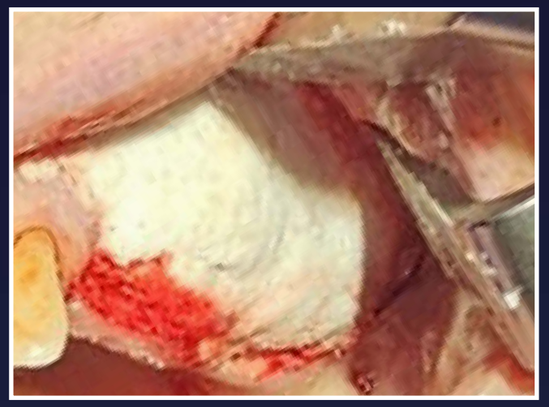

5. Intraoperative augmentation - EthOss® Bone Graft grafted over tenting sutures

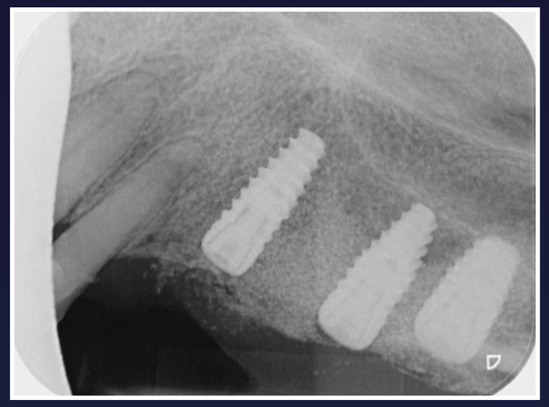

6. Post-op radiograph



7. Implants after exposure - 4 months post-op

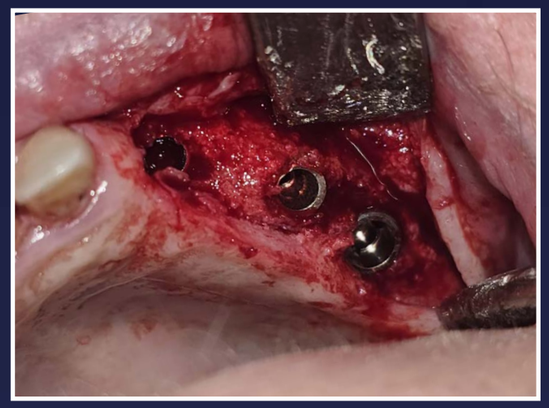

8. Implants after exposure - 4 months post-op

Staged ridge regeneration using a tenting suture technique



9. Post-op radiograph - implants after exposure

Complex maxillary implant rehabilitation with grafting

PATIENT BACKGROUND

The patient presented with failing maxillary dentition including implants. Imaging showed limited posterior bone.

SUMMARY OF TREATMENT

CBCT assessment and model-based planning defined implant positions and the surgical approach. Zygomatic implants were placed across the maxilla, with EthOss® Bone Graft. Postoperative imaging documented implant positions, and treatment was completed with a full-arch fixed restoration.

KEY TAKEAWAYS

- Cross-sectional imaging and model-based planning supported implant positioning in challenging maxillary anatomy.
- Adjunctive grafting was used for sites with deficient bone volume.
- The surgical and restorative stages were planned together to support full-arch rehabilitation.



Dr Costa Nicolopoulos

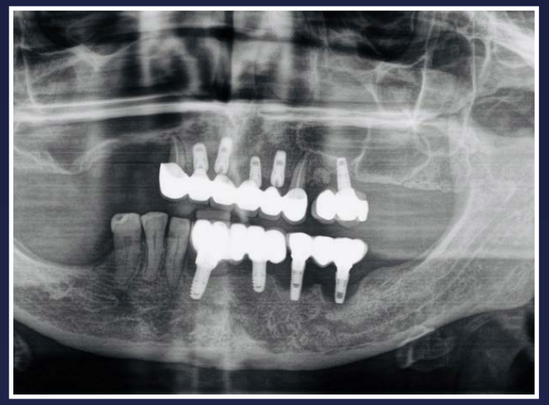

1. Pre-op radiograph

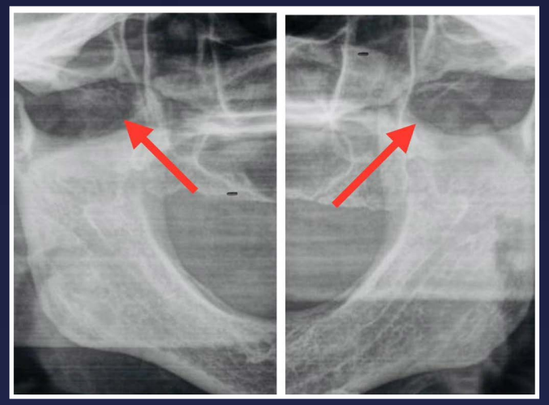

2. Detail of posterior maxillary bone deficiency



3. Pre-op clinical view

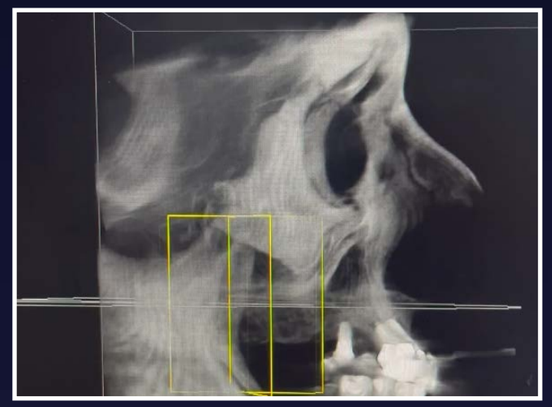

4. Sagittal CBCT planning view

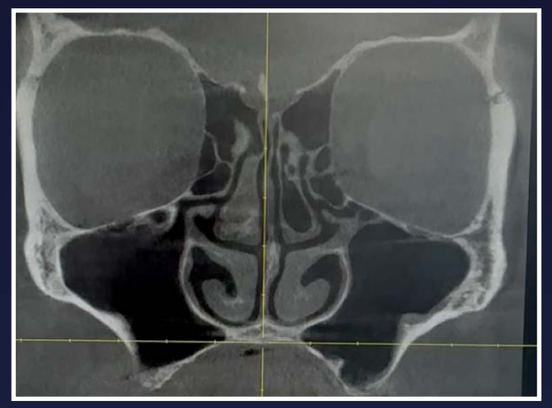

5. Coronal CBCT planning

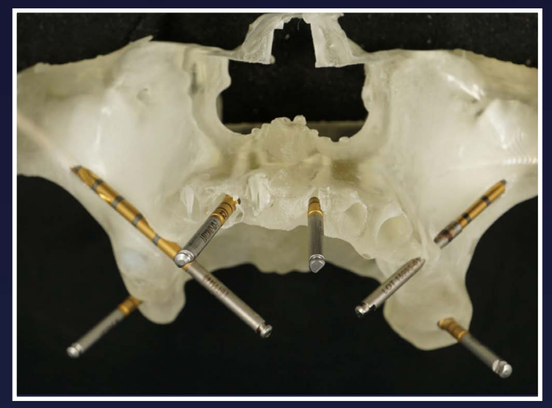

6. Surgical planning model

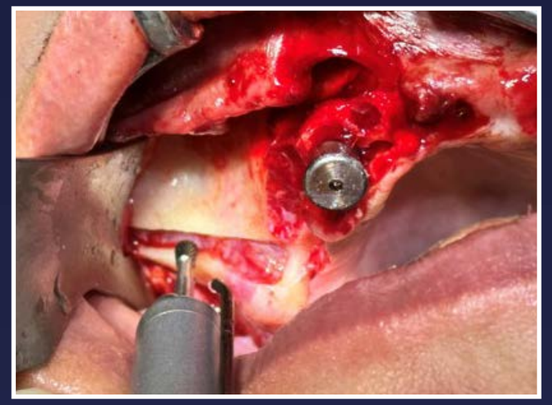

7. Osteotomy preparation

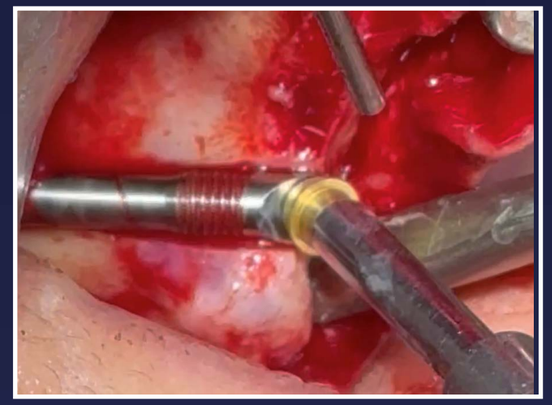

8. Zygomatic implant placement



9. Grafting around the implant sites



10. Grafting around the implant sites



11. Implant site preparation



12. Implant placement

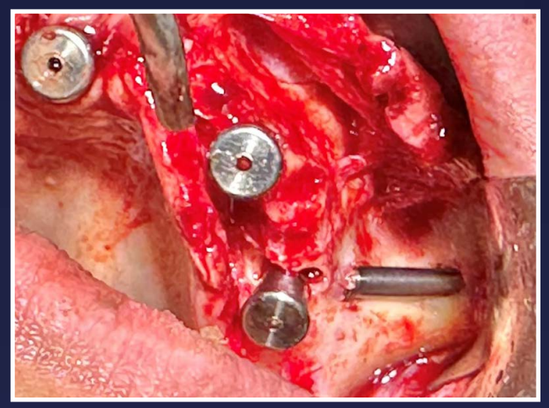

13. Implant placement



14. Grafting around the implant sites

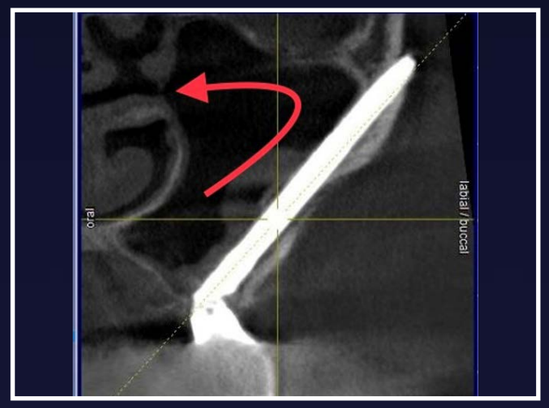

15. Post-op CBCT review

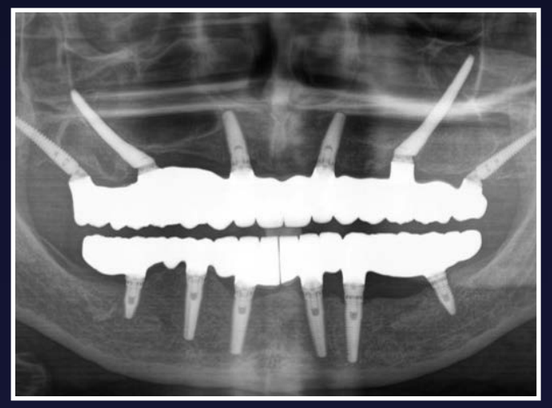

16. Post-op OPG review

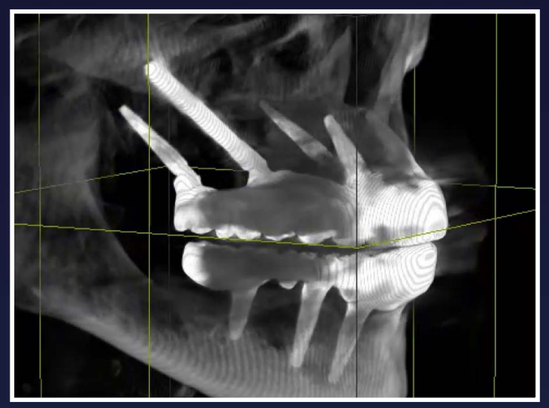

17. Post-op CBCT review

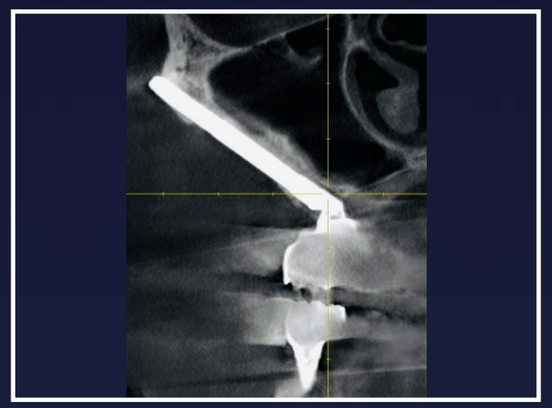

18. Post-op CBCT review



19. Post-op CBCT review



20. Final full-arch restoration - 18 months post-op

Full-arch maxillary implant rehabilitation

PATIENT BACKGROUND

The patient presented with a failing maxillary dentition and required full-arch implant rehabilitation.

SUMMARY OF TREATMENT

Following extraction and site preparation, zygomatic implants were placed. EthOss® Bone Graft was used at deficient sites for simultaneous bone regeneration. A provisional full-arch prosthesis was prepared, and postoperative CBCT and panoramic imaging documented implant positions.

KEY TAKEAWAYS

- Full-arch treatment requires prosthetically driven implant planning before surgery.
- Simultaneous grafting can address local defects when implants achieve suitable primary stability.
- Thorough degranulation and stable graft placement are essential before closure.



Dr Che Chao



1. Initial situation

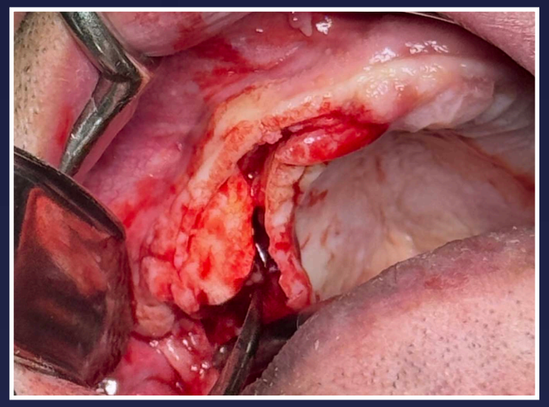

2. A pedicled partial thickness flap was harvested from the palatal aspect at site 15 for standby use

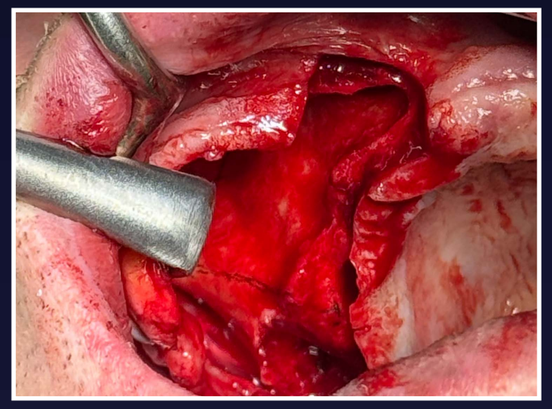

3. Raise the flap to expose cheekbones

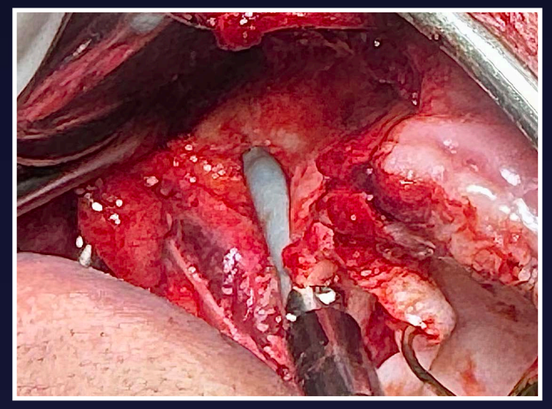

4. Maxillary surgical approach and zygomatic fixture placement

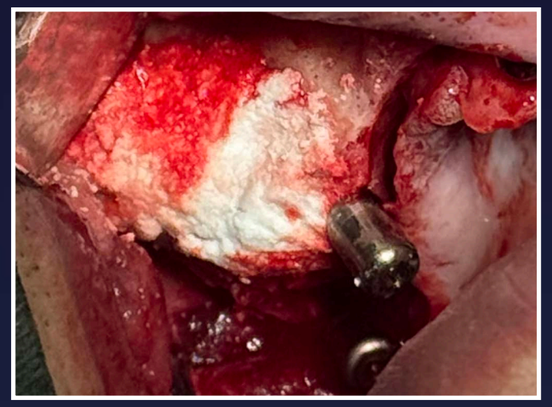

5. Placement of EthOss® Bone Graft 1.5cc



6. The incision was sutured and primary closure achieved



7. Provisional full-arch prosthesis with zygomatic implants

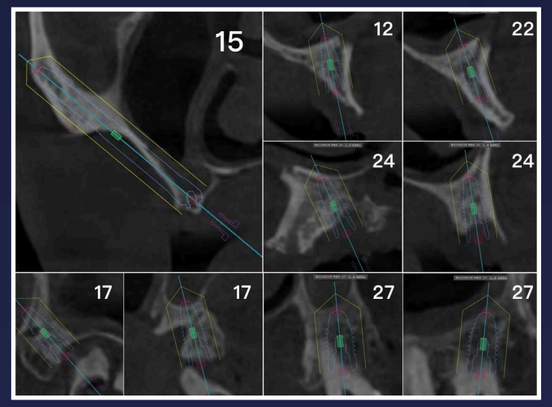

8. CBCT planning view

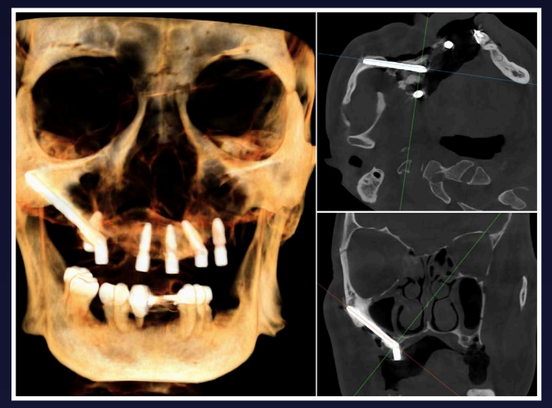

9. Maxillary implants in situ



10. Post-op panoramic radiograph



11. The provisional crown was seated



12. Provisional maxillary restoration in situ

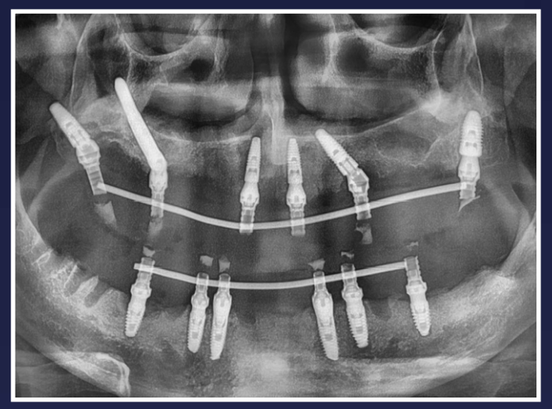

13. 19 days post maxillary surgery, mandibular implants were placed and immediately loaded



14. 3 months post maxillary surgery, the patient returned to the clinic with good oral hygiene



15. The temporary denture was intact and the occlusal relationship was stable

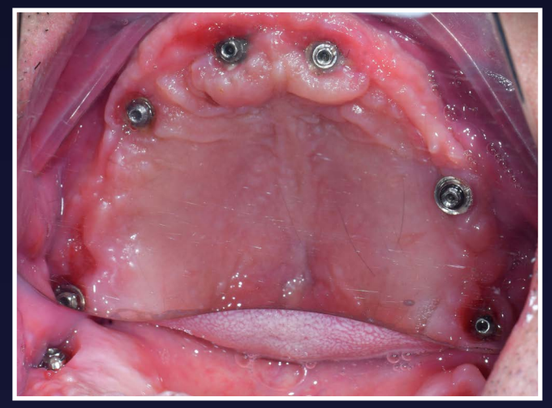

16. The soft tissues healed well and the keratinised gingiva was sufficient



17. Buccal soft tissue of zygomatic implant is good quality, no risk of gingival recession

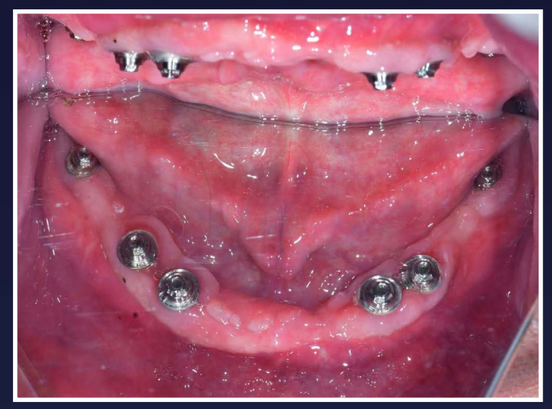

18. Healthy mandibular gingiva and sufficient keratinised gingiva



19. 3-months post-op, CBCT shows that the buccal and cervical bone augmentation areas of zygomatic implants had good osteogenesis and there was no adverse image in the maxillary sinus

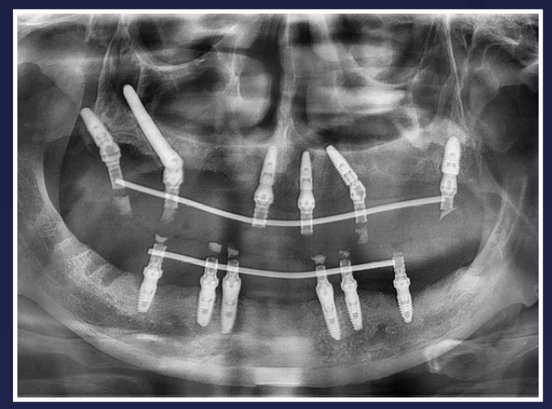

20. 3-months post-op, panoramic shows all implants had good osseointegration

Push-in: simultaneous implant placement

PATIENT BACKGROUND

64-year-old female
Non-smoker

SUMMARY OF TREATMENT

A raised flap revealed a large post XLA defect in site 46 filled with granulation tissue. After thorough degranulation, EthOss® Bone Graft was placed to fill the defect and the implant was pushed into the set material. After 10 weeks the implant was uncovered and restored with a screw-retained crown. Site 47 was later replaced with an implant.

KEY TAKEAWAYS

- Waiting 3–4 weeks after extraction gives soft tissue closure and makes primary closure over the graft easier.
- The push-in technique allows grafting and implant placement in one surgery, even in a large defect.
- Correct mixing of EthOss is essential, because the set material stabilises the implant.
- Restored at 10 weeks, with long-term stable bone.



Dr Peter Fairbairn

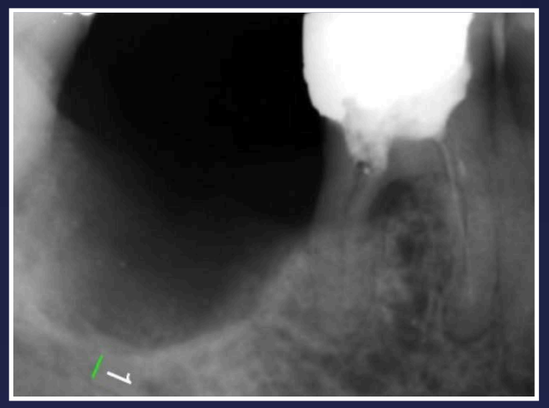

1. Initial situation

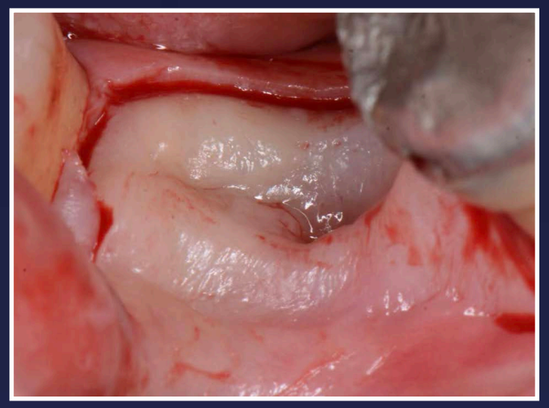

2. 3-4 weeks healing

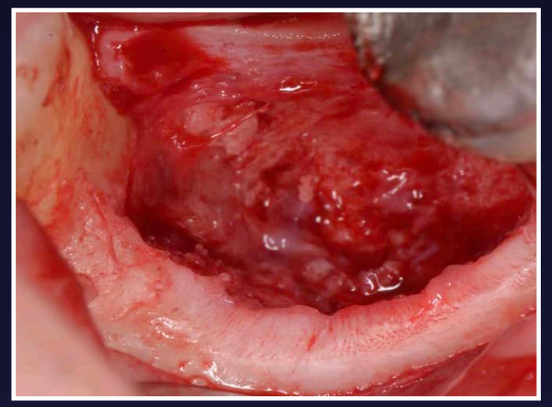

3. Defect

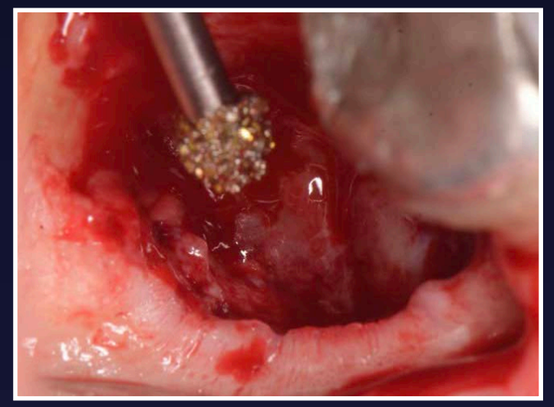

4. Degranulation with EthOss® degranulation burs



5. EthOss Bone Graft placed

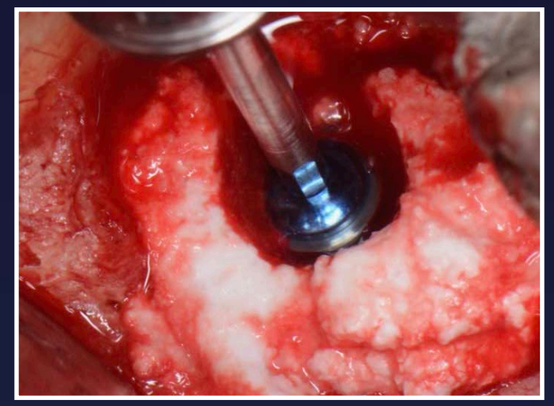

6. Pushed into the EthOss Bone Graft

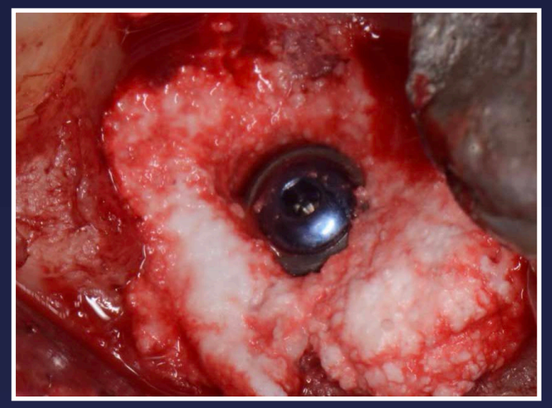

7. Implant in situ within the set EthOss Bone Graft



8. Radiograph - post-op

Push-in: simultaneous implant placement

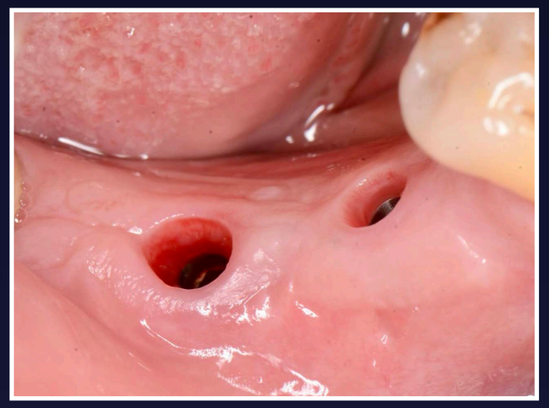

9. Clinical view - 10 weeks post implant placement



10. Clinical view - sites 46 and 47 restored

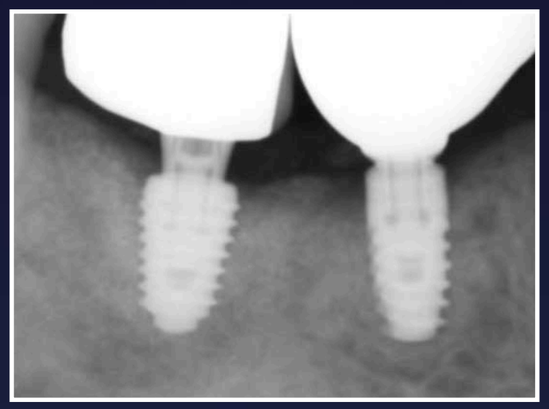

11. Radiograph - 46 and 47 restored



12. Clinical view - 3 years post-op

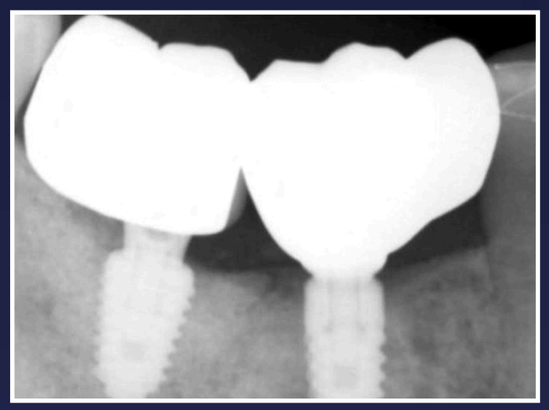

13. Radiograph - 3 years post-op

ethOss Grow Stronger

EthOss® Grow Stronger®

EthOss Regeneration Ltd
8 Ryefield Court, Ryefield Way
Silsden, West Yorkshire
BD20 0DL
UK
+44 (0)1535 843106
info@ethoss.dental
www.ethoss.dental

All Rights Reserved
© Copyright 2026

"Ethoss" and "Grow Stronger" are registered trade marks in several states worldwide in the name of Ethoss Regeneration Ltd.